



DR. SAMUEL HAHNEMANN
GERMANY

SEXOLOGY & INFERTILITY

Vision of Impossible to Possible

**Treatment of
Incurable Diseases
Like Cancer, Kidney
Failure, Coma, Surgical,
Autoimmune, Life Style
& Life Threatening
Diseases**



PROF. DR. ARPIT CHOPRA JAIN

M.D Homoeopathy

Critical and Surgical Disease Specialist (India)

**INVENTOR OF
AAROGYA SUPER SPECIALITY MODERN HOMEOPATHY**

COMPLETE, EASY SAFE, FAST & COST-EFFECTIVE CURE



Dr. Arpit Chopra Jain M.D Homeopath

Critical and Surgical Disease Specialist

Dr. Arpit Chopra Jain: Transforming Global Healthcare with Aarogya super Speciality Modern Homeopathy.

Dr. Arpit Chopra Jain, a pioneer in advanced homeopathic medicine, is set to present groundbreaking clinical data comprising over 3,000 successfully treated cases of critical and surgical diseases — all cured without the need for surgery. This revolutionary treatment approach, developed and practiced exclusively by Dr. Jain, utilizes high-potency homeopathic medicines formulated by him, offering fast, safe, and side-effect-free results.

With over 21 years of experience, Dr. Jain has dedicated his life to providing an alternative yet powerful medical solution that not only preserves the body's original organs but also ensures deep, lasting cures. **His work has gained national and international recognition. He has been honored by India's Vice President, Defense Minister Shri Rajnath Singh, Health Minister Shri J. P. Nadda, and several other dignitaries.** In acknowledgment of his contributions, he has also received a prestigious honorary doctorate from the USA.

Dr. Arpit Chopra Jain proudly represents India on the international stage as the **Homeopathic Representative for BRICS (Russia)** and continues to raise the global profile of homeopathy through his one-of-a-kind center based in Indore, Madhya Pradesh, India. From this single center, he has reached and treated patients from over 19 countries, offering remote consultations and delivering life-changing results globally.

Recently, **Dr. Jain was invited as the Guest of Honor at the highly esteemed United Nations Global Excellence Awards held at the UN Headquarters in New York, hosted by the United Nations Global Peace Council.** This momentous occasion was a testimony to his relentless commitment and global vision for homeopathy.

His work is supported by real, verifiable patient testimonials, including pre- and post-treatment reports, available on his official website and YouTube channel. These authentic stories reflect the effectiveness and rapid healing power of his treatment.

This book is a humble attempt to introduce Dr. Jain's extraordinary journey and his mission — to make the world healthier without surgery, promoting natural healing through scientifically advanced homeopathic medicine. His goal is to create a safer, more cost-effective, and organ-preserving healthcare alternative for patients across the globe.





The identity of any person is his real wealth.

INTRODUCTION

Inventor of Aarogya Super Speciality Modern Homoeopathy, revolutionized treatment for complex diseases

Professor Dr. Arpit Chopra Jain

Professor Dr. **Arpit Chopra Jain**, with over 20 years of medical experience and research, has revolutionized classical homeopathy by developing a future-oriented, super-speciality modern homoeopathy treatment system. His innovative approach has given new physical, mental, and social life to thousands of patients who were once considered incurable, including those suffering from nearly 300 different diseases such as cancer, kidney failure, coma, aplastic anemia, and other serious conditions requiring surgical intervention. In doing so, he has also fulfilled the World Health Organizations (WHO) belief that true health encompasses physical, mental, and social well-being.

Originally from Chhattisgarh, Dr. Arpit Chopra Jain received his primary education in his home state before moving to Indore to pursue a Bachelors degree in Homeopathy. After completing his BHMS, he earned an MD in Homeopathy from DKMM Homoeopathic Medical College in Aurangabad, Maharashtra. During his studies and career, he worked alongside many renowned allopathic doctors in Indore and other locations, acquire practical experience and contributing to medical advancements.

Currently, Dr. Arpit Chopra Jain is providing medical services through the Aarogya Super Speciality Modern Homoeopathy Clinic, located at Janjirwala Square in Indore, where he leads a team of experienced professionals. In addition to his clinical work, Dr. Arpit Chopra Jain plays a pivotal role in shaping homeopathic education as an educator at RN Kapoor Homoeopathic Medical College. His research focuses on complex blood-related diseases, including aplastic anemia and sickle cell anemia.. Driven by a commitment to innovation, Dr. Jain has been nationally and internationally recognized for his groundbreaking contributions to the treatment of complex and incurable diseases. His exceptional service during the COVID-19 pandemic further highlights his dedication to advancing modern homeopathic medicine.

Many of Dr. Arpit Chopra Jain's patients regard him as a godsend, praising his unwavering commitment to serving humanity. Beyond his medical practice, Dr. Arpit Chopra Jain, who hails from a family of 19 physicians, is making significant contributions to society and the Nation.

He firmly believes that Aarogya Super Speciality Modern Homoeopathy - instant, effective, affordable, and without side effects is the future of homoeopathy. While homoeopathy may have originated in Germany, Dr. Arpit Chopra Jain is confident that India's revolutionary modern homoeopathic medical system will one day be recognized globally, inscribing India's name in golden letters on the world health chart. He and his team are making every possible effort to achieve this vision and will continue to do so.



Golden India's Revolutionary Discovery: Pioneering the Future of Healthcare with Advanced Homoeopathy

Homoeopathy, a system of alternative medicine established over 200 years ago by German physician Dr. Samuel Hahnemann, has experienced widespread adoption across various countries, including India. However, over time, it faced criticism and was even banned in certain regions due to persistent myths and misconceptions, such as its alleged placebo effect. Critics claimed that homoeopathic remedies were ineffective, slow to act, and not backed by scientific evidence, leading to widespread skepticism among both the public and the scientific community.

One significant issue was that classical homoeopathy relied heavily on treating patients based on symptoms alone, without extensive clinical documentation or diagnostic reports. This absence of empirical evidence made it challenging to validate its effectiveness through conventional medical research methods.

In response to these challenges, Dr. Hahnemann later developed a more potent form of homoeopathic medicine, known as the 50 millesimal potency, or 5 million power. However, by the time this advancement was introduced, classical homoeopathy had already established deep roots, and the lack of continued research, documentation, and clinical validation led to its gradual decline in some regions.

Recognizing the need to address these limitations, Professor Dr. Arpit Chopra Jain, with over 20 years of clinical and hospital experience, pioneered a groundbreaking approach known as Super Speciality Modern homoeopathy. Utilizing the powerful 50 lakh potency homoeopathic medicines, along with mother tinctures, biochemic treatments, and dilutions, Dr. Jain's revolutionized the practice by effectively treating severe autoimmune conditions, including cancer, kidney failure, aplastic anemia, sickle cell anemia, rheumatoid arthritis, ankylosing spondylitis, and many other life-threatening illnesses. This innovative treatment approach has produced remarkable results, enabling patients suffering from complex and incurable diseases to recover without any side effects or lifelong medication dependency. Dr. Jain's method has proven particularly effective in cases previously deemed untreatable, such as patients in comas, those with brain tumors, or those in the terminal stages of illness.



His success extends beyond India, benefitting patients in countries such as Pakistan, Dubai, Bangladesh, the United States, and the United Kingdom.

A key differentiator of Super Speciality Modern Homoeopathy is its integration of clinical pathology alongside traditional symptom-based diagnosis. Dr. Jain's has meticulously collected pre- and post-treatment test reports from over 3,000 successfully treated patients, along with their written testimonials and interviews, both online and offline. This substantial body of evidence aims to secure recognition for his treatment methodology within the broader medical community, ensuring future generations of homoeopathic practitioners can offer hope to patients who might otherwise remain hopeless.

Dr. Jain's innovative work continues to shape the future of homoeopathy providing a new path forward for both patients and healthcare providers worldwide.



Complete Cure, Permanent, Easy, Safe, Fast, Cost Effective.

Aarogya Super Specialty Modern Homoeopathy -

It is a modern medical science which incorporates the basic nature of homoeopathy and keeps it as its basis and includes many other new features.



Easy Method -

In Aarogya Super Speciality Modern Homoeopathy, a variety of homoeopathic medicines are utilized, including decimal potency, centesimal potency, 50 millesimal potency, mother tinctures, biochemic medicines, The method of administering these medicines is straightforward and can be easily followed in the prescribed dosage under the guidance of a qualified homoeopathic doctor. One of the unique aspects of Aarogya Super Speciality Modern Homoeopathy is that it does not work with the traditional restrictions often associated with homoeopathic treatment, such as avoiding strong-smelling substances during medication. Due to the high quality and potency of the medicines used, these minor misconceptions hold no relevance in this advanced system of treatment. This approach allows for effective treatment without the need for strict dietary restrictions, making it more accessible and easier for patients to adhere to. Aarogya Super Speciality Modern Homoeopathy excels in providing top-tier treatment with minimal medication, even for complex and difficult-to-treat conditions. In this system, various diseases are treated directly and comprehensively, whether through homoeopathic medicines alone or in combination with supportive medicines from other medical systems, depending on the patients condition and the nature of the disease. This holistic approach ensures that patients receive the most effective and personalized care

Harmless Medical Method -

One of the most remarkable aspects of Aarogya Super Speciality Modern Homoeopathy is its safety profile, even when high potencies are used. Unlike conventional treatments where the risk of side effects increases with the dosage of active ingredients, homoeopathic medicines are carefully prepared through a process called potentiation. In this process, the original substance is diluted while simultaneously increasing its potency. This unique method ensures that only a minimal amount of the chemical or raw material remains in the final product. As a result, Aarogya Super Speciality Modern Homoeopathy offers highly effective treatments without the risk of harmful side effects. The approach is practically unmatched in other branches of medical science, where larger doses of active substances can often lead to adverse reactions. In this way, modern homoeopathy provides a safe and natural healing method, making it an ideal option for individuals seeking a harmless yet potent solution to their health issues.

Fast Aggressive Treatment -

One of the most remarkable aspects of Aarogya Super Speciality Modern Homoeopathy is its fast and aggressive healing process, setting it apart from conventional homoeopathy. In this advanced system, medical expertise is combined with cutting-edge technology, including computerized software, to ensure rapid, accurate diagnosis and treatment. Doctors utilize a vast array of over 4,000 potent medicines, with strengths ranging from zero potency to an astonishing 50 lakh potency, making the treatment scientifically robust and effective for a wide range of diseases. The precision of this method allows doctors to quickly gather and analyze detailed information about a patients condition, helping them select the most suitable remedy. This tailored approach ensures that even severe, surgical, or seemingly incurable conditions are addressed efficiently and effectively. What makes this treatment truly revolutionary is its ability to provide fast relief without any side effects, transforming it into a powerful, unique, and highly reliable branch of medical science.

Complete cure of diseases from the root -

Aarogya Super Speciality Modern Homoeopathy aims to heal the patient completely body, mind, and soul ensuring not only recovery from current ailments but also preventing the recurrence of diseases throughout life. This holistic approach to treatment is a crucial aspect of any effective medical science.

This fast and aggressive treatment approach embodies the future of homoeopathy, offering hope to patients facing complex diseases while maintaining the core principles of safety, simplicity, and efficacy.

Cost-Effective Treatment with Aarogya Super Speciality Modern Homoeopathy

Despite its advanced and multifaceted approach, Aarogya Super Speciality Modern Homoeopathy remains highly affordable and accessible, making it a preferred choice for many. Compared to other medical systems, it offers a cost-effective solution while providing complete, safe, and test treatment. This affordability, combined with its ability to deliver immediate results without harmful side effects, has contributed to the growing global popularity of modern homoeopathy. Today, homoeopathy is trusted by millions, with affordable medicines available to those in need. Every fourth person in the world now benefits from homoeopathy in some form, relying on its holistic and comprehensive approach to healthcare.



Dr. Arpit Chopra Jain, M.D. in Homoeopathy and the inventor of Aarogya Super Speciality Modern - Homoeopathy, has been instrumental in making this revolutionary treatment accessible to people from all walks of life. His commitment to providing effective, affordable, and harmless treatment has redefined the landscape of healthcare, offering hope and healing to thousands.



Dr. Arpit Chopra (Jain)
 M.D. HOMOEOPATHY
 Inventor of Aarogya Super Speciality Modern Homoeopathy



Aarogya Super Speciality Modern Homoeopathy



Successful Treatment of Critical Health Conditions

Dr. Jain's innovative treatment method has shown exceptional results in managing and curing serious health conditions, including:

- Cancer
- Kidney Diseases
- Coma
- Blood Disorders such as sickle cell anemia and aplastic anemia
- Arthritis
- Autoimmune Diseases
- Neurological Disorders
- Heart Diseases
- Skin Conditions like psoriasis and dermatitis

Through a deep understanding of the body's internal balance, Aarogya Super Speciality Modern Homoeopathy targets the root causes of these diseases, promoting natural self-healing without the need for invasive procedures or lifelong medications.

Revolutionizing Disease Treatment

Aarogya Super Speciality Modern Homoeopathy, developed by Dr. Arpit Chopra Jain, has introduced a groundbreaking, holistic approach to treating a wide range of complex and chronic diseases. This method offers a comprehensive, harmless, cost-effective, and permanent solution, achieving remarkable success where conventional treatments often fall short.

Efficacy Across a Wide Range of Diseases

With a proven record of success in treating nearly 300 different diseases, Aarogya Super Speciality Modern Homoeopathy offers relief from conditions that affect various aspects of health. Patients suffering from:

- Allergies
- Womens Health Issues
- Urological and Gastric Problems
- Rheumatoid Arthritis
- Pediatric Conditions
- Spinal Cord Disorders

have all experienced life-changing results through this pioneering method.



A New Lease on Life

What truly sets this treatment apart is its ability to provide lasting and permanent relief. Patients who were previously dependent on lifelong medication or faced invasive surgeries have regained their health, returning to a normal, medication-free life. Aarogya Super Speciality Modern Homoeopathy continues to transform lives, offering a new, holistic approach for those suffering from complex and chronic diseases.

Infertility

Infertility has historically been a difficult and often distressing issue for many couples. It affects millions of people worldwide, with around 48 million couples and 186 million individuals struggling with infertility. Infertility can be defined as the inability to conceive after 12 months or more of regular, unprotected intercourse. This issue affects both men and women and is categorized into:



Primary infertility: The inability to conceive at all.

Secondary infertility: The inability to conceive after previously having a successful pregnancy.

However, Dr. Arpit Chopra Jain, with his Aarogya Super Speciality Modern Homoeopathy treatment, has brought hope and joy to many couples who had previously struggled with infertility. His treatment approach is based on years of research and a holistic understanding of the reproductive system. By addressing the root cause of infertility and balancing the body's natural functions, Dr. Arpit Chopra Jain has helped countless couples achieve the joy of parenthood without the need for invasive procedures like IVF.

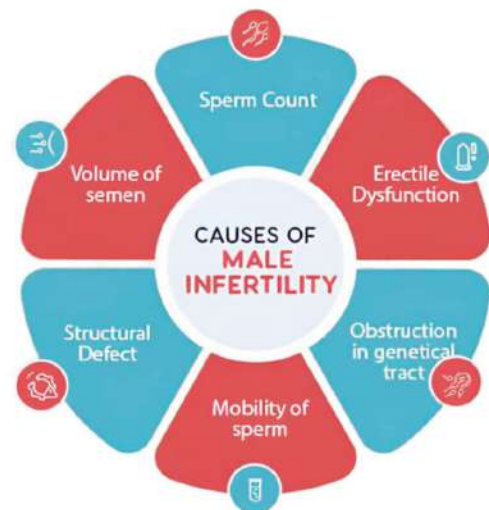



Despite the common misconception that infertility primarily affects women, male infertility is just as prevalent. Infertility has many potential causes, such as hormonal imbalances, genetic factors, lifestyle choices, infections, or even environmental conditions.

Traditionally, the medical approach to treating infertility involves extensive clinical tests and physical examinations. In many cases, assisted reproductive technologies (ART) such as IVF (In Vitro Fertilization) are recommended, which can be quite costly, physically demanding, and emotionally taxing. Despite the advances in allopathic medicine, these treatments do not always lead to successful pregnancies.

This modern homoeopathy approach not only improves the reproductive health of both men and women but also eliminates the emotional and physical strain often associated with conventional treatments. Couples who had lost hope have been able to conceive naturally, experiencing the happiness of starting a family, thanks to Dr. Arpit Chopra Jain 's groundbreaking treatments.



आरोग्य सुपर स्पेशलिटी मॉडर्न होम्योपैथिक क्लिनिक

Varicocele

2:26

Dr. Arpit Chopra Jain

Varicocele Patient Treatment ...

YouTube

VARICOCELE

वैरिकोसिल

अण्डकोष में गठान

बिना सर्जरी ईलाज

शेख निजामुद्दीन

सबसे सटीक

19:17

SATYA ULTRASOUND CENTRE

Hospital Road, Near Shiv Mandir, Bindusar Bujurg, Siwan

● Ultrasound ● C.T. Scan (96 Slice) ● Echocardiography ● Digital X-Ray

PATIENT NAME - AMIT KUMAR SAH
REFERRED BY DR. DR. PRADEEP KUMAR SUMAN, MBBS, MD (SURG)
INVESTIGATION - U.S.G. INGUINO - SCROTAL REGION

THANKS FOR REFERRING THE PATIENT

SCROTUM

TESTES :- Right - 3.7 cm x 2.9 cm x 2.0 cm
Left - 3.3 cm x 2.7 cm x 1.9 cm
Testes are normal in size, shape and homogeneous in echotexture.

EPIDIDYMS :- The epididymis measures (at head) 1.1 x 0.61 cm in right.
1.0 x 0.88 cm in left.
It is normal in thickness and echotexture.

** There is prominence of pampiniform plexus of veins - 2.1 mm diameter on right side.
There is mild flow reversal on Valsalva maneuver.
** There is prominence of pampiniform plexus of veins - 2.1 mm diameter on left side.
There is mild flow reversal on Valsalva maneuver.
** No hydrocele seen on both side.
** No inguinal hernia seen on both side.

IMPRESSION :- Grade II varicocele on both side.

Dr. Satya Prakash Shankaram

MBBS Civil Medical (M.C.C.E), Outpatient
M.D. Radiodiagnosis (M.C.A. India)
Ex. Senior Resident, S.P.S.C. Ludhiana
M.D. U.S.G. Medical College, Varanasi
Consultant Radiologist & Urologist
30 C 18, 1st Flg. No. - 4016

Please do not request of Sex Determination, We strictly avoid this test.
This Report is not valid for Medical legal purpose.

SATYA ULTRASOUND CENTRE

Hospital Road, Near Shiv Mandir, Bindusar Bujurg, Siwan

● Ultrasound ● C.T. Scan (96 Slice) ● Echocardiography ● Digital X-Ray ● Pathology

PATIENT NAME - AMIT KUMAR
REFERRED BY DR. DR. ARVIND KUMAR, MBBS
INVESTIGATION - U.S.G. SCROTUM

THANKS FOR REFERRING THE PATIENT

SCROTUM

TESTES :- Right - 3.9 cm x 3.3 cm x 2.4 cm
Left - 3.6 cm x 2.1 cm x 2.2 cm
Testes are normal in size, shape and homogeneous in echotexture.

EPIDIDYMS :-
The head of the epididymis measures 1.0 x 0.68 cm in right side
1.1 x 0.67 cm in left side
** Both epididymis is normal in thickness and echotexture.

** No fluid collection noted in both scrotum.
** No varicocele on both side.
** No inguinal hernia noted on both side.

IMPRESSION :- No significant abnormality noted in inguino-scrotal region.

After Dr Arpit Chopra Jain Modern Homoeopathy

Dr. Satya Prakash Shankaram

MBBS Civil Medical (M.C.C.E), Outpatient
M.D. Radiodiagnosis (M.C.A. India)
Ex. Senior Resident, S.P.S.C. Ludhiana
Ex. J.R. M.D. Medical College, Varanasi
Consultant Radiologist & Urologist
30 C 18, 1st Flg. No. - 4016

Please do not request of Sex Determination, We strictly avoid this test.

Varicocele cured By Dr Arpit chopra Jain Modern Hom...

YouTube

Varicocele

Also called: scrotum varicose veins

Overview Symptoms Treatment

Healthy Testicle

Varicocele

An enlargement of the veins within the scrotum.

A varicocele may develop as a result of poorly functioning valves that are normally found in veins. In other cases, it may occur from compression of a vein by a nearby structure.

Very common

More than 10 million cases per year (WHO)

Before treatment

After Modern Homoeopathy treatment

Dr. Satya Prakash Shankaram

VARICOCELE

Also called: scrotum varicose veins

Overview Symptoms Treatment

An enlargement of the veins within the scrotum.

A varicocele may develop as a result of poorly functioning valves that are normally found in veins. In other cases, it may occur from compression of a vein by a nearby structure.

Dr. Arpit Chopra Jain

VARICOCELE | Varicocele Cured

21:03

सबसे सटीक

मॉडर्न होमियोपैथी के द्वारा

Aarogya Super Speciality ...

वैरिकोसेल cured By Dr Arpit Chopra Jain Aarogya Super...

VARICOCELE

Also called: scrotum varicose veins

Overview Symptoms Treatment

An enlargement of the veins within the scrotum.

A varicocele may develop as a result of poorly functioning valves that are normally found in veins. In other cases, it may occur from compression of a vein by a nearby structure.

After Dr Arpit Chopra Jain Modern Homoeopathy treatment

VARICOCELE | Varicocele Cured By Dr Arpit Chopra Jain

2.8K views · 1y

VARICOCELE | Varicocele Cured By Dr Arpit Chopra Jain

3 views · 1y

VARICOCELE वैरिकोसेल CureD By Dr Arpit Chopra Jain ...

Chandia

बिना ऑपरेशन सर्जरी ईलाज

क्या आपको सभी डॉक्टरों ने ऑपरेशन की अंतिम सलाह दी है

अब नहीं कल्याण पड़ेगा या कोई सर्जरी

Dr. Arpit Chopra Jain

DR. SAMUEL SHANMUGAN GERMANY

VISION OF PERMANENT TREATMENT OF COMPLEX, INCURABLE & IMPOSSIBLE DISEASES

Like Cancer, Kidney, Coma, Surgery and Autoimmune is Now available in India

PROF. DR. ARPIT CHOPRA JAIN

MD Homeopathy Critical and Surgical Disease Specialist

INVENTOR OF AAROGYA SUPER SPECIALITY MODERN HOMOEOPATHY



आरोग्य सुपर स्पेशलिटी मॉडर्न होम्योपैथीक क्लिनिक

AAROGYA SUPER SPECIALITY MODERN HOMOEOPATHIC CLINIC

कमती कीमतें, उच्च गुणवत्ता वाली सेवाएँ

ऑनलाइन परामर्श सेवाएँ

डॉ. अरपि चोपड़ा जैन, आयुर्वेद विशेषज्ञ, अस्वास्थ्य से निपटने के लिए नवीन और सुरक्षित, प्रमाणित, वैश्विक, वैश्विक चिकित्सा, 300 प्रकार के अस्वास्थ्य जटिल रोगों की चिकित्सा

0731-4677076 | 91 89076-27914, 91 97130-92737, 91 97130-37737, 91 93404-95872, 91 79999-78894 | 91 97130-37737, 91 80451-32033

www.aarogyasuper.com
www.aarogyasuperindia.com
www.aarogyasuperindia.com

Address: 101, 102, 103, 104, Krishna Tower, Janajeevni Square, in front of Cureswell Hospital Road, New Palasia, Indore, Madhya Pradesh 452001

Email: arpitchojra23@gmail.com



DR. ARPIT CHOPRA JAIN
MD HOMOEOPATHY & CAPITAL & SURGICAL
DISEASES SPECIALIST

Varicocele - 5 yrs.
Grade II
Pain (+) on USG - dilation.
Painkiller occ.
0.6mm → 0.47 x 0.31 cm
Tiny calcification at head of left epididymis & scrotal sac - left side.
Rt side - Calcification 0.51 x 0.41 Head of left Rt epididymis & scrotal sac.
dilation - 2.2mm
Renal calculi - 4-5mm 2 calculi in left kidney.
2 in 1
10/20/2024
10/20/2024

Varicocele Patient Treatment - YouTube

VARICOCELE वैरिकोसेल
जड़कोष में गठन
का इलाज होना
संभव है

वैरिकोसेल cured By Dr Arpit Jain Aarogya Super...

VARICOCELE वैरिकोसेल Cured By Dr Arpit Chopra Jain ...

VISION OF PERMANENT TREATMENT OF COMPLEX, INCURABLE & IMPOSSIBLE DISEASES
Like Cancer, Kidney, Coma, Surgery and Alzheimer's are now available in India!

PROF. DR. ARPIT CHOPRA JAIN
MD Homoeopathy, Capital & Surgical Diseases Specialist

SHIVANI DIAGNOSTIC CENTRE

Pathology | Sonography | Digital X-Ray | Colour Doppler | ECG | Echocardiography | TMT

Lab ID: 13702250182 Registered on: 27-Feb-2005 19:12

Name: Mr. Nitin Patlya Sample Reported on: 27-Feb-2025 15:40

Sex/Age: Male / 30 Years Reg. Centre: Shivani Diagnostic Centre

INGUNO-SCROTAL SONOGRAPHY

RIGHT
Right testis = 3.7 x 2.1 x 2.7 cm (Vol. 11.2 cc)
Echotexture of right testis appears homogenous and normal.
Appr. 0.51 x 0.41 cm size tiny calcification seen at head of right epididymis & similar tiny calcifications also seen in scrotal sac s/o Epididymal calcifications.
Epididymis is normal in size, shape & echotexture.
No abnormal free fluid seen in right tunica vaginalis.
Spermatic cord appears normal in echotexture.
No scrotal wall thickening is seen.
There are dilated (2.2 mm) & tortuous venous channels seen along right spermatic cord and on doppler study no reflux on valsalva s/o Varicocele.
No defect seen in right inguinal region.

LEFT
Left testis = 4.0 x 1.8 x 2.7 cm (Vol. 10.7 cc)
Echotexture of left testis appears homogenous and normal.
Appr. 0.47 x 0.31 cm size tiny calcification seen at head of left epididymis & similar tiny calcifications also seen in scrotal sac s/o Epididymal calcifications.
Epididymis is normal in size, shape & echotexture.
No abnormal free fluid seen in left tunica vaginalis.
Spermatic cord appears normal in echotexture.
No scrotal wall thickening is seen.
There are dilated (2.6 mm) & tortuous venous channels seen along left spermatic cord and on doppler study no reflux on valsalva s/o Varicocele.
No defect seen in left inguinal region.

Before Treatment

IMPRESSION: BILATERAL VARICOCELE (GRADE II).

समर्पण
Imaging & Diagnostic

22/2 Yashwant Niwas Road, Indore (M.P.)
Plot No. 2, Dussehra Maidan Road, Bhawanipur Colony, Annapurna Main Road, Indore (M.P.)
www.samarpanimaging.com

After Dr Arpit Chopra Jain Modern Homoeopathy

PATIENT NAME:- MR.NITIN PATLYA DATE:- 10/05/2025
REF. BY :- DR. MRADULA JAIN AGE/SEX:-28Y/MALE

SCROTUM-USG

RIGHT TESTES:-
Right testes is normal in size, shape, position and echo pattern.
Measurement: Right Testis - 3.4 x 1.6 x 2.4 cm.
right Epididymis is normal in size and echo pattern.
No hydrocele on left side.
Left spermatic cord is normal

LEFT TESTES:-
Left testes is normal in size, shape, position and echo pattern.
Measurement - Left Testis - 4.3 x 1.7 x 2.8 cm.
No hydrocele on left side.
Left spermatic cord is normal

Mild prominence of pampiniform plexus of vessels seen along left epididymis, however no obvious reversal of flow seen maximum dilation measuring 1.5-2.0 mm.

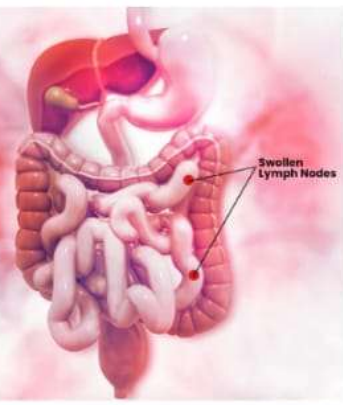IMPRESSION:-
Mild prominence of pampiniform plexus of vessels seen along left epididymis, however no obvious reversal of flow seen maximum dilation measuring 1.5-2.0 mm.

Advice:- Clinical correlation / Further evaluation.

DR. ANIT KUMAR TIWARI
H.D. RADIOLOGIST
REG. NO. 11339

MESENTERIC LYMPHADENITIS

Inflammation of lymph nodes



The mesentery is a fold of membrane that attaches the intestine to the abdominal wall and holds it in place. Mesenteric lymphadenitis is an inflammation of the lymph nodes in the mesentery. Lymphadenitis is a condition in which your lymph nodes become inflamed. 20-May-2021

SODANI DIAGNOSTIC CLINIC ISO: 9001:2015
(A unit of Sodani Hospitals & Diagnostics Pvt. Ltd.)
H.O. : L.G.-1, Morya Centre, Opp. Basket Ball Club, 16/1, Race Course Road, Indore (M.P.)
Phone : 0731 - 4756222, 9617779159

Patient Name : **Master. AARAV GUPTA**
DOB/Age/Sex : 6 years/Male
Mobile : 9754271260
Referred By : Dr. -

Sample ID : 4012201449
Organization : DIRECT
Registered : Oct 21, 2022, 11:39 a.m.
Collected On : Oct 21, 2022, 11:29 a.m.
Approved On : Oct 21, 2022, 11:49 a.m.

SONOGRAPHY

WHOLE ABDOMEN SONOGRAPHY

Hepatic contour is smooth & span (11.4 cm) is normal. Parenchymal echotexture is normal. No focal lesion is seen. Intrahepatic biliary radicles are undilated. Gall bladder is normally distended. Walls are thin. No sludge & calculi seen. No peri GB collection is noted.

Portal vein & CBD are normal in caliber. Pancreas is normal in shape & size. Parenchymal echoes are normal. Duct is undilated. Spleen is normal (7.8 cm). No focal lesion seen.

Both kidneys are normal in position & size. Right kidney is 7.5 x 2.8 cm & left is 7.5 x 3.4 cm in size. Cortical echoes are normal. Pelvicalyceal system is undilated. Both ureters are undilated. No calculi seen at PUJ & UVJ. Urinary bladder shows normal walls & echofree lumen. No intra luminal lesion or calculi seen. Prostate is normal for age.

No significant Ascites. No pleural effusion. Slightly thickened hypochoic wall of terminal ileum & caecum base with increased surrounding vascularity. Few enlarged mesenteric lymphnodes are seen with maintained fatty hilum, largest measures 14 x 10 mm.

[Impression]:
- No hepatobiliary lesion seen.
- Normal renal echoanatomy with undilated collecting system.
- Ileocecal inflammation with reactive lymphadenopathy.
Clinical correlation / further evaluation

DR. PRIYANKA PATEL
MD (Radiodiagnosis), Reg.No. MP 13154

before Treatment

SODANI DIAGNOSTIC CLINIC ISO: 9001:2015
(A unit of Sodani Hospitals & Diagnostics Pvt. Ltd.)
H.O. : L.G.-1, Morya Centre, Opp. Basket Ball Club, 16/1, Race Course Road, Indore (M.P.)
Phone : 0731 - 4756222, 9617779159

Patient Name : **Master. AARAV GUPTA**
DOB/Age/Sex : 6 years/Male
Mobile : 9754271260
Referred By : Dr. Chopra Arpit Jain (MD, Homeo)

Sample ID : 40122301449
Organization : DIRECT
Registered : Feb 04, 2023, 05:05 p.m.
Collected On : Feb 04, 2023, 05:12 p.m.
Approved On : Feb 04, 2023, 05:14 p.m.

SONOGRAPHY

WHOLE ABDOMEN SONOGRAPHY

Hepatic contour is smooth & span (9.9 cm) is normal. Parenchymal echotexture is normal. No focal lesion is seen. Intrahepatic biliary radicles are undilated.

Gall bladder is normally distended. Walls are thin. No sludge & calculi seen. No peri GB collection is noted.

Portal vein & CBD are normal in caliber. Pancreas is normal in shape & size. Parenchymal echoes are normal. Duct is undilated. Spleen is normal (7.0 cm). No focal lesion seen.

Both kidneys are normal in position & size. Right kidney is 8.0 x 3.3 cm & left is 8.2 x 3.6 cm in size. Cortical echoes are normal. Pelvicalyceal system is undilated. Both ureters are undilated. No calculi seen at PUJ & UVJ. Urinary bladder shows normal walls & echofree lumen. No intra luminal lesion or calculi seen. Prostate is normal for age.

No significant Ascites. No pleural effusion. No significant bowel wall thickening / dilatation or lymphnodes are noted.

[Impression]:
- No hepatobiliary lesion seen.
- Normal renal echoanatomy with undilated collecting system.
Clinical correlation / followup suggested

DR. RAJU PREMCHANDANI
MBBS, DMRE

After Dr Arpit Chopra Modern Homeopathic Treatment

सक्सेस स्टोरी
Cervical Lymphadenopathy
गर्दन की गाँठ का सफल ईलाज
मॉडर्न होमियोपैथी के द्वारा

Dr. Arpit Chopra Jain
(MD Homoeopathy)
Critical & Surgical Case Specialist

ABDOMINAL LYMPHADENOPATHY
LYMPHOMA CANCER
SUSPECTED CASE CURED
क्रिटिकल केस का सफल ईलाज
Mr. Satish Mahsare

Dr. Arpit Chopra Jain
(MD Homoeopathy)
Critical & Surgical Case Specialist

सक्सेस स्टोरी
मॉडर्न होमियोपैथी के द्वारा 14:38

* कैंसर * किडनी फेलियर * अस्पताल में गंभीर रूप से * भर्ती मरिजों का उपचार * कोमा * शल्य चिकित्सा योग्य रोग आँटो इन्फ्यून रोग * जीवनभर दवाई लेने वाले रोगों की रोकथाम एवं 300 प्रकार के असाध्य जटिल रोगों की चिकित्सा ।

आरोग्य सुपर स्पेशलिटी मॉडर्न होमियोपैथिक क्लीनिक

डॉ. अर्पित चोपड़ा (जैन)

COMPLETE CURE EASY SAFE, FAST & COST EFFECTIVE
आरोग्य
HOMOEOPATHY

Name : MR. HARSHAL PATIL
Referred By : DR. ARPIT CHOPRA
Drawn On : 17-Sep-2016 10:44
Accession No.: 1609107614

Age: 32 Years Sex : Male
Received On : 17-Sep-2016 10:46
Report Date : 20-Sep-2016



DEPARTMENT OF CLINICAL PATHOLOGY
SEMEN ROUTINE

Parameter	Result	Unit	Biological Reference Interval
-----------	--------	------	-------------------------------

Microscopic Examination

Sperm Count	NO SPERMATOZOA SEEN	million/ml	50 - 150
Agglutination	Nil		
Fructose Test	Positive		

Name : MR. HARSHAL PATIL
Referred By : DR. ARPIT CHOPRA
Drawn On : 10-Oct-2016 10:02
Accession No.: 1610104131

Age: 32 Years Sex : Male
Received On : 10-Oct-2016 10:04
Report Date : 16-Oct-2016



DEPARTMENT OF CLINICAL PATHOLOGY
SEMEN ROUTINE

Parameter	Result	Unit	Biological Reference Interval
-----------	--------	------	-------------------------------

Microscopic Examination

Sperm Count	85	million/ml	50 - 150
Sperm Motility			
Grade 0 (Non-Motile)	10	%	0 - 40
Grade 1 (Sluggish)	30	%	60 - 100
Grade 2 (Fair)	40	%	60 - 100
Grade 3 (Good)	10	%	60 - 100
Grade 4 (Excellent)	10	%	

Name : MR. MANISH MASATKAR
Referred By : DR. ARPIT CHOPRA
Drawn On : 08-Mar-2015 14:13
Accession No.: 1503101680

Age: 31 Years Sex: Male
Received On : 08-Mar-2015 14:15
Report Date : 08-Mar-2015

Before treatment



DEPARTMENT OF CLINICAL PATHOLOGY
SEMEN ROUTINE

Parameter	Result	Unit	Biological Reference Interval
Physical Examination			
Quantity	5.0	ml.	
Colour	Milky White		
Viscosity	Viscous		
Liquification Time	30		
Microscopic Examination			
Sperm Count	10	million/ml	50 - 150

After treatment

Name : MR. MANISH MASATKAR
Referred By : DR. ARPIT CHOPRA
Drawn On : 22-Mar-2015 11:21
Accession No.: 1503105290

Age: 31 Years Sex: Male
Received On : 22-Mar-2015 11:22
Report Date : 22-Mar-2015



DEPARTMENT OF CLINICAL PATHOLOGY
SEMEN ROUTINE

Parameter	Result	Unit	Biological Reference Interval
Physical Examination			
Quantity	2.0	ml.	
Colour	Milky White		
Viscosity	Viscous		
Liquification Time	40		
Microscopic Examination			
Sperm Count	50	million/ml	50 - 150

Patient Name: **MR. RAFIQUE PATEL** Age/Sex: **23 Yr / M**
 Ref.By: **DR. PENDHARKAR SHAILAJA** Date: **08/Dec/2015**
 MD
 Consultant: **DR. KOCHHAR KAPIL**
M.B.B.S., M.S.

Before Treatment

SEMEN EXAMINATION

Method of Collection : Masturbation
 Liquefaction Time : 30 Min.

Semen Collection at : Lab.
 Semen Preserved at : 37 Degree

GENERAL EXAMINATION

Quantity : **0.20 ml**
 Appearance : **Mucoid(+)**

Co lour : **Milky White**
 Frank Blood : **Absent**

CHEMICAL EXAMINATION

Reaction : **Alkaline**

Fructose Test : **Q.N.S.**

MICROSCOPIC EXAMINATION

No. of Spermatozoa Per ml. : **NIL**

After Treatment

Name : **MR. RAFIQ PATEL**
 Referred By : **DR. ARPIT CHOPRA**
 Drawn On : **24-Jun-2016 11:08**
 Accession No.: **1608109836**

Age: **24 Years** Sex : **Male**
 Received On : **24-Jun-2016 11:10**
 Report Date : **24-Jun-2016**

**DEPARTMENT OF CLINICAL PATHOLOGY
SEMEN ROUTINE**

Parameter	Result	Unit	Biological Reference Interval
Physical Examination			
Quantity	3.0	ml.	
Colour	Milky white		
Viscosity	Viscous		
Liquefaction Time	30		
Microscopic Examination			
Sperm Count	65	million/ml	50 - 150
Sperm Motility			
Grade 0 (Non-Motile)	95	%	0 - 40
Grade 1 (Sluggish)	05	%	60 - 100
Grade 2 (Fast)	00	%	00 - 00

Name : MR. RONAK JAIN
Referred By : ARPIT CHOPRA
Drawn On : 02-Sep-2013 11:38
Accession No.: 1309200144

Before treatment

Age: 23 Years Sex: Male
Received On : 02-Sep-2013 11:43
Report Date : 02-Sep-2013



DEPARTMENT OF CLINICAL PATHOLOGY
SEMEN ROUTINE

Parameter	Result	Unit	Biological Reference Interval
Physical Examination			
Quantity	3.5	ml.	
Colour	MILKY WHITE		
Viscosity	Viscous		
Liquification Time	45		
Microscopic Examination			
Sperm Count	48	million/ml	50 - 150

Name : MR. RAUNAK JAIN
Referred By : ARPIT CHOPRA
Drawn On : 09-Oct-2013 13:01
Accession No.: 1310201132

After treatment

Age: 23 Years Sex: Male
Received On : 09-Oct-2013 14:13
Report Date : 09-Oct-2013



DEPARTMENT OF CLINICAL PATHOLOGY
SEMEN ROUTINE

Parameter	Result	Unit	Biological Reference Interval
Physical Examination			
Quantity	1.5	ml.	
Colour	MILKY WHITE		
Viscosity	Viscous		
Liquification Time	35		
Microscopic Examination			
Sperm Count	82	million/ml	50 - 150

Name : MR. VIVEK SHARMA
Referred By : DR. ARPIT CHOPRA
Drawn On : 12-Mar-2016 12:05
Accession No.: 1603105032

Age: 32 Years Sex : Male
Received On : 12-Mar-2016 12:06
Report Date : 12-Mar-2016



DEPARTMENT OF CLINICAL PATHOLOGY
SEMEN ROUTINE

Parameter	Result	Unit	Biological Reference Interval
Physical Examination			
Quantity	2.5	ml.	
Colour	MILKY WHITE		
Viscosity	Viscous		
Liquification Time	30		
Microscopic Examination			
Sperm Count	50	million/ml	50 - 150

after treatment

DEPARTMENT OF CLINICAL PATHOLOGY
SEMEN ROUTINE

Parameter	Result	Unit	Biological Reference Interval
Physical Examination			
Quantity	3.5	ml.	
Colour	MILKY WHITE		
Viscosity	Viscous		
Liquification Time	30		
Microscopic Examination			
Sperm Count	85	million/ml	50 - 150

Name : MR. VIVEK SHARMA
Referred By : DR. ARPIT CHOPRA
Drawn On : 12-Mar-2016 12:05
Accession No.: 1603105032

Age: 32 Years Sex : Male
Received On : 12-Mar-2016 12:06
Report Date : 12-Mar-2016



DEPARTMENT OF CLINICAL PATHOLOGY
SEMEN ROUTINE

Parameter	Result	Unit	Biological Reference Interval
Physical Examination			
Quantity	2.5	ml.	
Colour	MILKY WHITE		
Viscosity	Viscous		
Liquification Time	30		
Microscopic Examination			
Sperm Count	50	million/ml	50 - 150

after treatment

DEPARTMENT OF CLINICAL PATHOLOGY
SEMEN ROUTINE

Parameter	Result	Unit	Biological Reference Interval
Physical Examination			
Quantity	3.5	ml.	
Colour	MILKY WHITE		
Viscosity	Viscous		
Liquification Time	30		
Microscopic Examination			
Sperm Count	85	million/ml	50 - 150

Peyronie's disease

Also called: penile fibrosis

Overview

Treatments

Symptoms

Spec

Fibrous scar tissue inside the penis that causes curved, painful erections.

Peyronie's disease is caused by repeated penile injury, typically during sex or physical activity.

Benign prostate enlargement

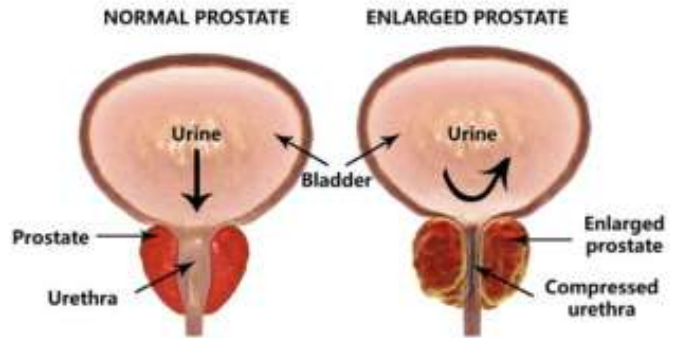
Also called: BPH

OVERVIEW SYMPTOMS TREATMENTS NEWS

Age-associated prostate gland enlargement that can cause urination difficulty.

This type of prostate enlargement isn't thought to be a precursor to prostate cancer.

BENIGN PROSTATIC HYPERPLASIA



Rishabh Diagnostics

53, Rajula Boring, Compound, Shakti Nagar, Raipur (M.P.)
Ph. - 07412254040 / 07412491440

NAME- ARVIND BHATT 58Y
REFERRED BY - DR. ABHI MEHRA MS

DATE- 31.7.20

USG WHOLE ABDOMEN

LIVER: is normal in size, shape and echotexture. No focal mass or diffuse lesion seen. IHBR are not dilated. Hepatic veins normal.

GALL BLADDER: is minimally distended, wall appears smooth and regular. No calculus and focal lesion seen. Pericholecystic areas normal.

PANCREAS: Pancreas is normal in size, shape and echogenicity. no focal and diffuse lesion seen. pancreatic duct is not dilated.

SPLEEN: is normal in size, shape and echotexture. Parenchyma is homogenous, no focal or diffuse lesion seen. Splenic vein measures normal.

BOTH KIDNEY: Are normal in shape size and echogenicity. Parenchyma is normal in thickness. Corticomedullary differentiation is clear. pelvical system is compact. No hydronephrosis or renal calculus seen. Perirenal areas normal. Both ureter are not dilated. R.K-9.4x4.7CMS. L.K.9.9x5.2-CMS.

AORTA AND IVC: Are normal.

BLADDER: well distended, wall thickness normal, no evidence of any calculus and mass lesion seen. Pyle void-328cc, post void-114cc.

PROSTATE: is enlarged in size (approx. VOL-50.5CC) shape and echogenicity. NO focal and mass lesion seen.

No pleural effusion, ascitis or free fluid seen.

BOTH ILIAC FOSSA: Normal, no focal mass lesion seen.

IMPRESSION - ENLARGED PROSTATE WITH SIGNIFICANT POST VOID URINE.



Rishabh Diagnostics

53, Rajula Boring, Compound, Shakti Nagar, Raipur (M.P.)
Ph. - 07412254040 / 07412491440

NAME- ARVIND BHATT 59Y
REFERRED BY - DR. ARPIT SEN

DATE- 1.10.20

USG WHOLE ABDOMEN

LIVER: is normal in size, shape and increased echotexture. No focal mass or diffuse lesion seen. IHBR are not dilated. Hepatic veins normal.

GALL BLADDER: is well distended, wall appears smooth and regular. No calculus and focal lesion seen. Pericholecystic areas normal.

PANCREAS: Pancreas is normal in size, shape and echogenicity. no focal and diffuse lesion seen. pancreatic duct is not dilated.

SPLEEN: is normal in size, shape and echotexture. Parenchyma is homogenous, no focal or diffuse lesion seen. Splenic vein measures normal.

BOTH KIDNEY: Are normal in shape size and echogenicity. Parenchyma is normal in thickness. Corticomedullary differentiation is clear. pelvical system is compact. No hydronephrosis or renal calculus seen. Perirenal areas normal. Both ureter are not dilated. R.K-10.3x5.2CMS. L.K-10.1x5.2CMS.

AORTA AND IVC: Are normal.

BLADDER: well distended, wall thickness normal, no evidence of any calculus and mass lesion seen.

PROSTATE: is enlarged in size (approx. VOL-25.3CC) , shape and echogenicity. NO focal and mass lesion seen.

No pleural effusion, ascitis or free fluid seen.

BOTH ILIAC FOSSA: Normal, no focal mass lesion seen.

IMPRESSION - FATTY LIVER GRADE I, ENLARGED PROSTATE.

DR. ARPIT CHOPRA (JAIN)
M.D. HOMOEOPATHY
Critical & Surgical Diseases Specialist

102, First Floor Krishna Tower
In Front of Currawell Hospital
Janpur Wala Square, INDORE (M.P.)

Time : Morning : 10 am to 3 pm
Evening : 05 pm to 10 pm
Sunday : 12 am to 3 pm

Dr. Arvind Bhatt
Rattam
HTN : 3 year
DM : 2 year
Enlarged prostate : 20 days - 10 pm
- Dysuria
- frequency of micturition
- Burning micturition

Brain Haemorrhage
Depression

Vol 114cc



COMPLETE CURE, EASY, SAFE, FAST & COST EFFECTIVE

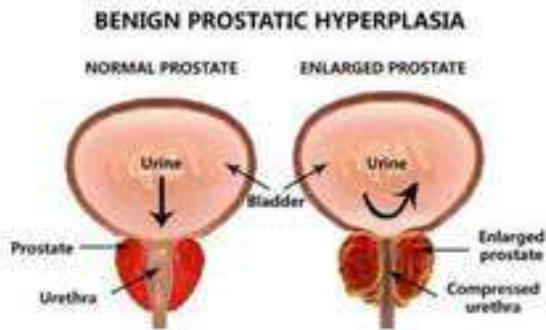
MODERN
आरोग्य
ERN

HOMOEOPATHY

Dr. Arpit Chopra (Jain)
M.D. HOMOEOPATHY
(Critical & Surgical Diseases Specialist)

9907527914, 9713037971
9713092737, 79999979

Benign prostatic hyperplasia (BPH) is an enlargement of the prostate gland. It commonly occurs as men age. It can contribute to bothersome lower urinary tract symptoms (LUTS).



The prostate goes through two main growth cycles during a man's life. The first occurs early in puberty, when the prostate doubles in size. The second phase of growth starts around age 25 and goes on for most of the rest of a man's life. BPH most often occurs during this second

कैंसर, किडनी केलिब्र, अस्पताल में गंभीर रूप से यती मरिजों का उपचार, कोमा, शल्य चिकित्सा योग्य रोग, ऑटो इम्प्यून रोग, जीवनभर दवाई लेने वाले रोगों की रोकथाम एवं 300 प्रकार के असाध्य जटिल रोगों की चिकित्सा।

आरोग्य सुपर स्पेशलिटी माईन होमियोपैथी
कम्प्लिट, परमाणु, ईजी, सेफ, फास्ट एण्ड सोस्ट इफेक्टिव

102, प्रथम मंजिल, सुभा टॉवर, कपोदेन हॉस्पिटल के सामने, जयदेवराव चौक, न्यू चतौस, इन्दौर म.प्र.
99075 27914 फ़ोन; 0731-4277076, 79999 78884
www.homoeopathvsnr.in, www.danovahomoeopathvsnr.com, Email : arisht@homa23@gmail.com

ATUL JAIN SONOGRAPHY & DIAGNOSTIC CENTER ANAND RAJAP INDORE

Dr. Atul Kalaria
MBBS, DMRD Reg. 4377
Consultant (+ On, Hospital)
• Sarda Hospital (SIRC) Gandhinagar
• Shree Memorial Hospital (SMMHC) Indore
Mob. 9710003803

KUB-MALE

Right Kidney: Size is normal (18.3 x 3.9 cm). Cortical outline - smooth. Cortical thickness - 3.6cm. No hydronephrosis seen. Cortical echotexture - normal. Cortical nodularity - None. Present.

Left Kidney: Size is normal (18.6 x 3.7 cm). Cortical outline - smooth. Cortical thickness - 3.6cm. No hydronephrosis seen. Cortical echotexture - normal. Cortical nodularity - None. Present.

Both kidneys shows few (at least 2-4) calculi of about 3-4 mm size in upper- mid-lower calyx.

Both kidney also shows few cortical based foci of calcification about 2-3 mm size in the upper-lower pole.

Bilateral pelvi-calyceal systems and ureters are unaltered.

No obvious calculus seen at U-V-JT region.

Urinary bladder is well distended and appears normal. Wall thickness normal. Lumen is anechoic. Prevoid volume - 408 cc. Post void residual is - 30 cc.

Prostate is enlarged in size (4.4 x 3.6 x 3.8 cm) and normal echogenicity (weight approximately 18 gm).

before treatment

THE BIOPSS
A Cancer Diagnosis & Treatment Institute
An ISO 9001:2015 Certified Organization

NAME	CHHOTI LAL PACHLANIYA	AGE / SEX	74Y/M	OPD
REF. BY:	DR ARPIT CHOPDA MD	DATE	22 June 2022	

USG - WHOLE ABDOMEN

Clinical history: Increased frequency & urgency
Patient cooperation: Good
Comments: None

Liver (12 cm) is normal in size, shape and echotexture. Portal and hepatic veins appear normal. No focal lesion is seen. No BPH dilatation seen.

Gall bladder is normal in size, shape and echotexture. Portal vein (1.0 cm) and CBD appears normal. **Pancreas** appears normal. **Spleen (10.7 x 6.0 cm)** is normal in size & echotexture.

Kidneys: RX (10.6 x 4.8 cm) & LX (10.9 x 4.7 cm).

Both kidneys are normal in size, shape, position and reveals mild altered echogenicity with multiple concretions in upper mid and lower calyceal region. A tiny non-obstructive calculus of approximately 0.8 x 0.5 cm size is noted in lower calyceal region of right kidney. Few foci of early nephro-calcinosis is noted on left.

No significant intra-abdominal lymphadenopathy. No evidence of ascites.

Urinary bladder appears normal with normal caliber walls and anechoic contents. Post void residual volume is significant (88 ml).

Prostate appears normal in size with mild enlarged medial lobe (peripheral zone) indenting the bladder base. Hypertrophic transitional zone is also seen in maximum dimension measuring approximately 2.5 x 3.4 x 3.8 cm (volume: 17.77 cm³, weight: 18.95 gm). The periprostatic structure appears normal.

Impression:

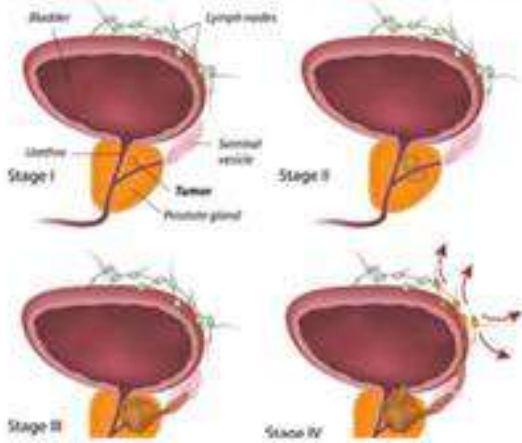
Normal volume of prostate with mild enlarged medial lobe (peripheral zone) indenting the bladder base. Hypertrophic transitional zone is also seen. Postvoid volume is significant 88 ml.

Mild altered echogenicity with multiple concretions in upper- mid and lower calyceal region. A tiny non-obstructive calculus of approximately 0.8 x 0.5 cm size in lower calyceal region of right kidney. Few foci of early nephro-calcinosis on left.

after Modern homoeopathy treatment

DR. RAJESH KUMAR GADTA
MD, DMRD, MBBS
Consultant, Cross Hospital, Indore
Radiology (CT & MR) and Interventional Radiology
Specialized in: Angiography, Interventional Radiology, Image Guided Biopsy, etc.

STAGES OF PROSTATE CANCER



08
 Prostate Cancer Treated with High PSA

Handwritten notes in Hindi describing the patient's condition and treatment progress. The text includes details about the patient's age, symptoms, and the effectiveness of the treatment.

Central Lab Dr. Vinita Kothari, MD

After Dr Arpit Chopra Modern Homeopathy treatment

Medical report from Central Lab, Dr. Vinita Kothari, MD, detailing laboratory results and a clinical note. The note mentions the patient's condition and the impact of the treatment.

SODANI DIAGNOSTIC CLINIC

before treatment

Medical report from Sodani Diagnostic Clinic, dated before treatment. It includes patient information, test results, and a clinical note.

SODANI DIAGNOSTIC CLINIC

After Dr Arpit Chopra Modern Homeopathy treatment

Medical report from Sodani Diagnostic Clinic, dated after treatment. It shows updated test results and a clinical note reflecting the patient's progress.

Benign prostatic hyperplasia

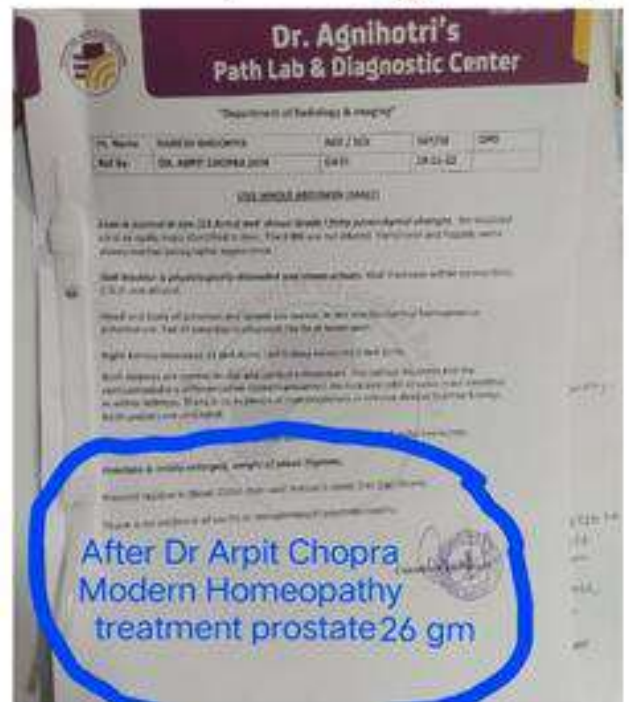
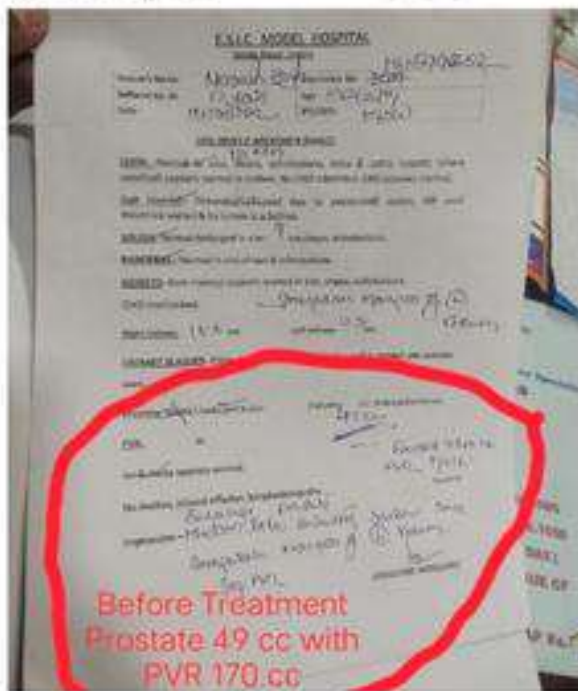
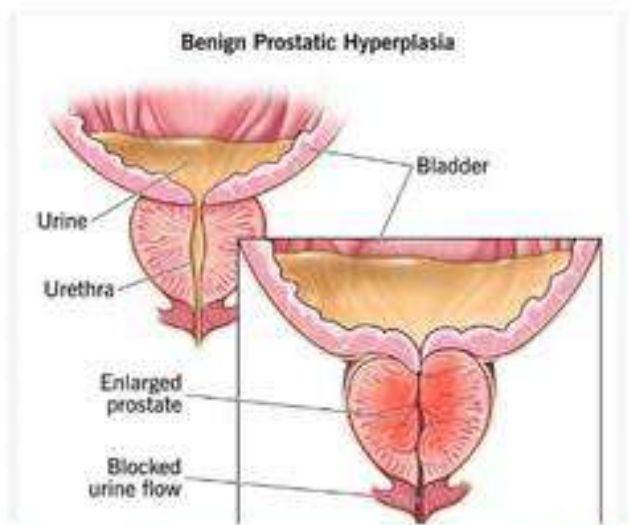
Also called: BPH

- Overview
- Symptoms
- Treatments

Age-associated prostate gland enlargement that can cause urination difficulty.

This type of prostate enlargement isn't thought to be a precursor to prostate cancer.

Very common



Prostatomegaly 50 gm with 114 ...
Dr Arpit Chopra's Su...
205 views · 1 year a...



BPH(Benign Prostatic Hyperp...
Dr Arpit Chopra's Su...
314 views · 1 year a...



Prostate Enlargement | B...
Dr Arpit Choopa's Su...



Prostate Enlargement Tre...

Erectile dysfunction

Also called: ED, impotence

Overview

Symptoms

Treatment

Occurs when a man can't get or keep an erection firm enough for sexual intercourse.

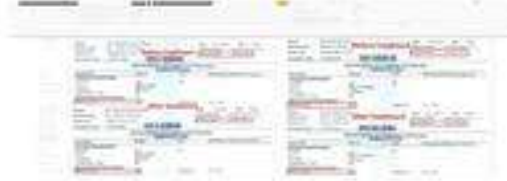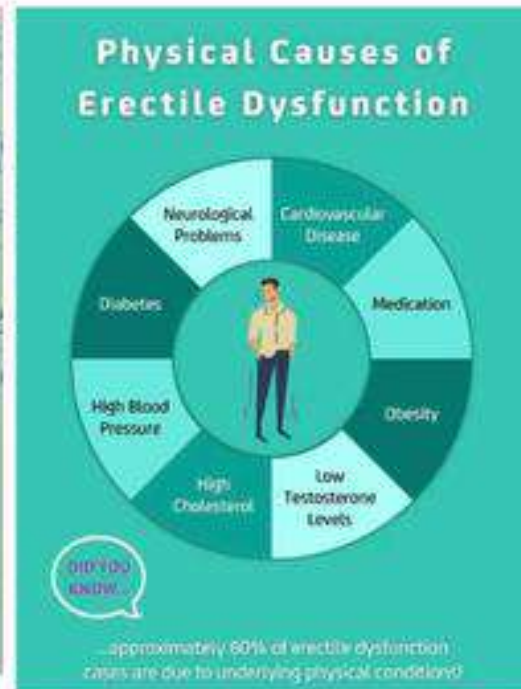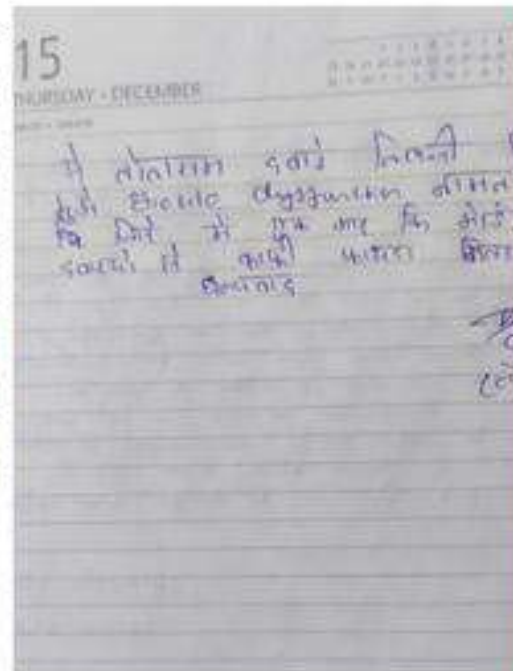
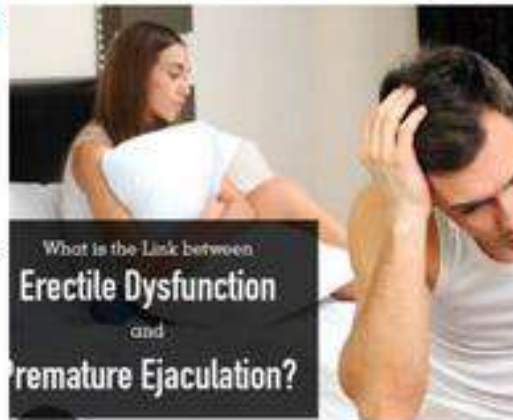Erectile dysfunction can be a sign of a physical or psychological condition. It can cause stress, relationship strain and low self-confidence.

Very common

More than 10 million cases per year (India)

Treatable by a medical professional

Usually self-diagnosable



Varicocele

Also called: scrotum varicose veins

- Overview
- Symptoms
- Treatment

An enlargement of the veins within the scrotum.

A varicocele may develop as a result of poorly functioning valves that are normally found in veins. In other cases, it may occur from compression of a vein by a nearby structure.

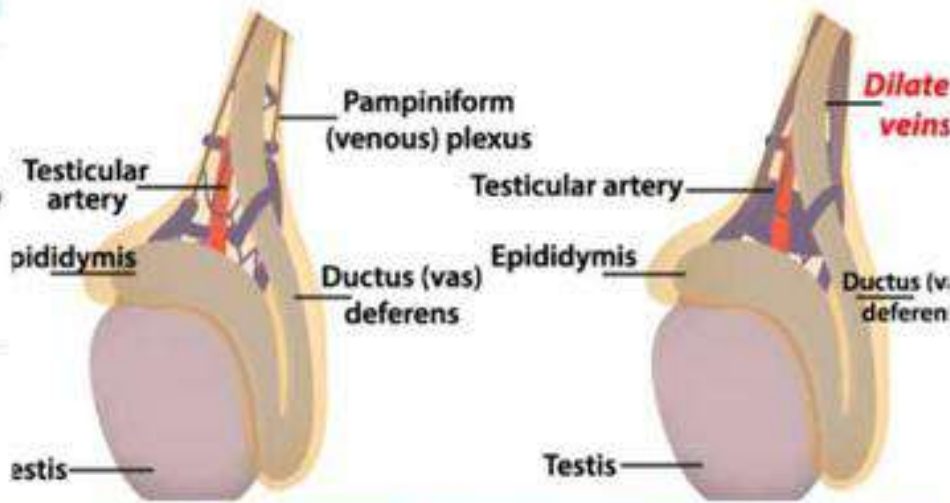
Very common

More than 10 million cases per year (India)

Varicocele

Healthy Testicle

Varicocele



Dr. Shweta Jain Sonography & Diagnostic Centre

Dr. Shweta Jain
Consultant Sonographer & Obstetrician

Dr. Ajeet Kapadia
Date: 26/02/2022

USG Scrotum - Doppler

- Both testis are normal in size, shape & echotexture with normal vascularity. Right testis measures app. 3.7x2.5x2.3cm. Left testis measures app. 3.8x2.2x2.4cm.
- Both epididymis shows mildly heterogeneous echotexture.
- Bilateral scrotal wall appears normal.
- Mild reactionary free fluid seen in bilateral scrotal sac.
- Impression - Dilated veins app. 1.5cm - 2cm in right side & app. 1.5cm - 2.5cm in left side were seen in bilateral pampiniform plexus of veins showing reflux on valsalva varicocele (Grade-I right side & Grade-II left side).
- Both epididymis shows mildly heterogeneous echotexture / chronic epididymitis.
- Mild reactionary free fluid seen in bilateral scrotal sac.

Kindly correlate clinically **before treatment**

Dr. Shweta Jain
Radiologist

SODANI DIAGNOSTIC CLINIC

Dr. Raju Preshraddha
MBBS DMRD

SCROTAL SONOGRAPHY (COLOR DOPPLER)

RIGHT SCROTUM:
Right testis is normal in shape, size (3.5 x 2.3 cm) and echotexture. Epididymis is normal in length and width. No fluid seen in tunica vaginalis.

Color doppler study show:
Veins are normal in caliber. No reflux seen on valsalva. Testicular flow is normal.

LEFT SCROTUM:
Left testis is normal in shape, size (4.6 x 2.4 cm) and echotexture. Epididymis is normal in length and width. No fluid seen in tunica vaginalis.

Color doppler study show:
Veins are normal in caliber. No reflux seen on valsalva. Testicular flow is normal.

Impaired Region:
No significant haemorrhage seen.

Impression:
- Normal size testes.
- No fluid seen in tunica vaginalis.
- No reflux in veins with valsalva.
Clinical correlation / Followup suggested.

After Modern Homoeopathy treatment

06
THURSDAY - OCTOBER

Varicocele

02/10/22

Dr. Arun Choudhary
MBBS DMRD

कैंसर, किडनी फेलियर, अस्पताल में गंभीर रूप से भर्ती मरिजों का उपचार, कोमा, शल्य चिकित्सा योग्य रोग, ऑटो इम्यून रोग, जीवनभर दवाई लेने वाले रोगों की रोकथाम एवं 300 प्रकार के असाध्य जटिल रोगों की चिकित्सा।

आरोग्य सुपर स्पेशलिटी माईन होमियोपेथी

कम्प्लिट, परमानेंट, ईजी, सेफ, फास्ट एण्ड कॉस्ट इफेक्टिव

102, प्रथम मंजिल, कृष्णा टॉवर, गवर्नमेंट हॉस्पिटल के सामने, जंजीरवाड़ा बीरगढ़, न्यू दिल्ली, इण्डिया, न.प्र.
99075 27914 | संपर्क : 0731-4977076, 79669 78804
www.homoeopathyroute.in, www.aarogyaahomeopathyindia.com | Email : arunichouda23@gmail.com

Benign prostatic hyperplasia

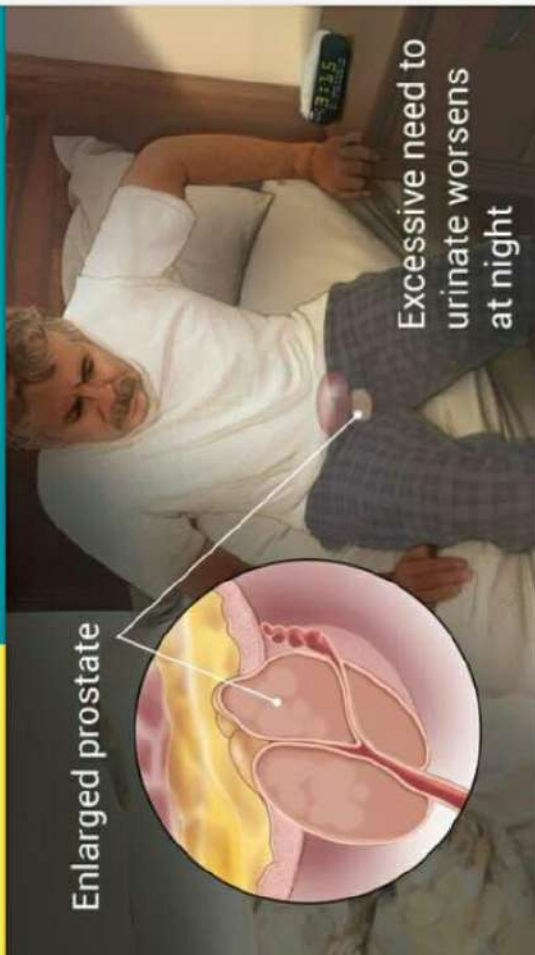
Also called: BPH



TREATMENTS

SYMPTOMS

ABOUT



Enlarged prostate

Excessive need to urinate worsens at night

Age-associated prostate gland enlargement that can cause urination difficulty.

Very common

More than 10 million cases per year (India)



Treatable by a medical professional



Requires a medical diagnosis



Lab tests or imaging often required

X-RAY HOUSE & IMAGING CENTRE

Breast Imaging Center

- Digital Mammography
- Colour Doppler & Sonography
- 3D / 4D Sonography
- Digital X-Ray
- Digital OPG

E-4/A, HIG Main Road, Near L.I.G. Square, Indore (M.P.) Ph : 0731-2551158, 4291159

Date- 10-03-18

Mr. Shankardyal Sharma 66 Yrs, M

Ref. By : Dr. Arpit Jain MD (Homeo)

ABDOMINAL - SONOGRAPHY

Liver is normal in size and echogenicity. No focal lesion or biliary dilatation. CBD and Portal V. are normal.

Gall bladder is physiologically distended and nonlithiasic. GB wall is normal. No pericholecystic collection.

Spleen is normal in size and echogenicity.

Pancreas is normal in size and echotexture. No calcification or signs of pancreatitis.

Both Kidneys are normal in size, shape, position and outline. Right Kidney measures- 9.4 x 4.9 cm & Left Kidney measures- 9.8 x 5.0 cm. Renal cortical echogenicity is normal with fair c/c and c/m differentiation. No renal mass/ abscess/ perinephric collection.

There is no renal calculus or hydronephrosis on either side.

Urinary bladder is normal in shape and outline. Distended urinary bladder measured- 292 ml. Bladder wall is normal. No vesical calculus or a filling defect.

Post void residual volume is 40 ml.

Prostate is enlarged 5.42 x 4.68 x 4.50 cm = 59.66 gms.

Seminal vesicles are normal in size and echogenicity.

There is no lymphadenopathy / ascites or pleural effusion.

IVC and abdominal aorta appear normal.

X-RAY HOUSE & IMAGING CENTRE

Breast Imaging Center

- Digital Mammography
- Colour Doppler & Sonography
- 3D / 4D Sonography
- Digital X-Ray
- Digital OPG

E-4/A, HIG Main Road, Near L.I.G. Square, Indore (M.P.) Ph : 0731-2551158, 4291159

Date- 16-5-18

Mr. Shankar Dayaal Sharma

Ref. By : Dr. Arpit Chopra MD (Home)

ABDOMINAL - SONOGRAPHY

Liver is normal in size and echogenicity. No focal lesion or biliary dilatation. CBD and Portal V. are normal.

Gall bladder is physiologically distended and nonlithiasic. GB wall is normal. No pericholecystic collection.

Spleen is normal in size and echogenicity.

Pancreas is normal in size and echotexture. No calcification or signs of pancreatitis.

Both Kidneys are normal in size, shape, position and outline. Right Kidney measures- 9.1 x 5.2 cm & Left Kidney measures- 9.8 x 4.8 cm. Renal cortical echogenicity is normal with fair c/c and c/m differentiation. No renal mass/ abscess/ perinephric collection.

There is no renal calculus or hydronephrosis on either side.

Urinary bladder is normal in shape and outline. Distended urinary bladder measured- 367 ml. Bladder wall is normal. No vesical calculus or a filling defect.

Post void residual volume is 103 ml.

Prostate measures 4.98 x 4.10 x 3.60 cm = 39.12 gms.

Seminal vesicles are normal in size and echogenicity.

There is no lymphadenopathy / ascites or pleural effusion.

IVC and abdominal aorta appear normal.

Dr. Rajendra Bhandari
M.D. (Radiodiagnosis)
R. No. - 8574

This report is not valid for reproduction.

Hydrocele



ABOUT

SYMPTOMS

TREATMENTS

A fluid-filled sac around a testicle, often first noticed as swelling of the scrotum.

Common

More than 1 million cases per year (India)

Suyash Hospital Pvt. Ltd.
(CIN : U85110MP1991PTC00836)

ISO 9001
CERTIFIED COMPANY

Reg. No. : 48091
Name : MR. SHAILENDRA PATODIYA
Age/Sex : 27 YEARS/MALE
Consultant Doctor : HOSPITAL CASE
Referred by :

VisitID No. : 0171812081
Order Date : 02/08/2017
Report Date : 02/08/2017

**SONOGRAPHY
COLOR DOPPLER SCROTAL**

Examination performed with 5 - 10 MHz. Probe .

Wide necked (1.7 cms) reducible inguino- scrotal hernia noted.

Rt. scrotal sac also show moderate free hydrocoele (approx. 30ml).

Lt. scrotal sac show plenty of varicoes veins extending inferiorly as for as bottom of testes. Largest vein measures 3.8mm.

The testes are of normal size (4x3x2.5cms), shape and display homogenous, smooth low level echostructure. The color & PW doppler examination show normal perfusion.

The spermatic cord show normal flow pattern on color & PW doppler.

There is no abnormal fluid in tunica vaginalis on Lt. side.

IMPRESSION :

- * RL INGUINO-SCROTAL HERNIA.
- * RL HYDROCOELE
- * LT. VARICOCELE.

SODANI DIAGNOSTIC CLINIC
NO. : L.S.-1, Shree Centre, Opp. Reshet Ball Club, 101, Hansi Ganga Road, Indore (M.P.) ☎ 0731-663-6891

Dr. Chopra Anil Jain MD(Medical)

MR. SHAILENDRA PATODIYA
28 YEARS / MALE
28/08/2017

02/08/2017
02/08/2017

SCROTAL SONOGRAPHY (COLOR DOPPLER)

RIGHT TESTIS:
Right testis is normal in shape, size (4.6 x 3.0 x 2.1 cm = 16 cc) and echotexture.
Epididymis is normal in length and width. Epididymal head measuring 7.8 x 7.7 mm.
Color doppler study show :
Veins are normal in caliber. No reflux seen on valsalva.
Testicular flow is normal.

LEFT TESTIS:
Left testis is normal in shape, size (4.7 x 2.8 x 1.9 cm = 13.9 cc) and echotexture.
Epididymis is normal in length and width. Epididymal head measuring 8.2 x 9.4 mm.
No fluid seen in tunica vaginalis.
Color doppler study show :
Veins are dilated (3.6 mm) in supine position also. Reflux seen on valsalva.
Testicular flow is normal.

Inguinal Region
Indirect inguinal hernia is seen on right side containing omentum & free fluid. Communication is seen with tunica vaginalis. No bowel herniation or obstruction is seen at present scan.

[Impression] :

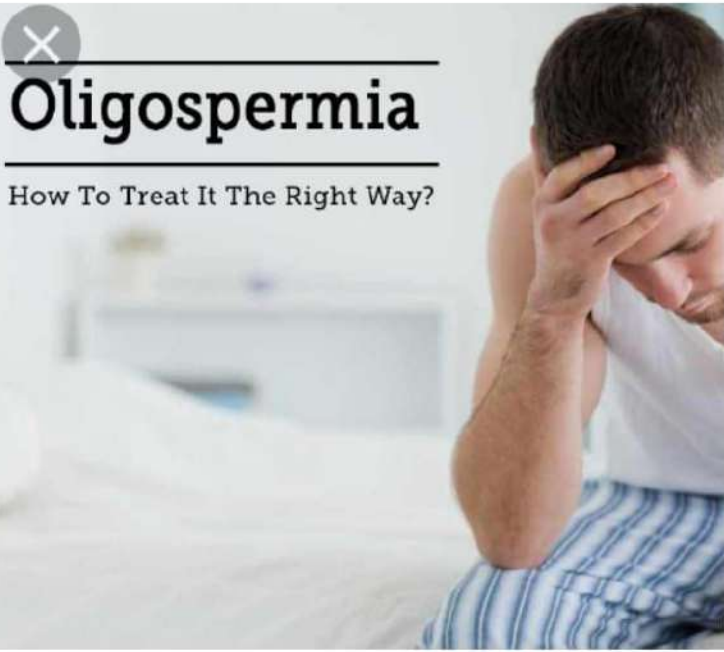
- Normal size testes.
- No fluid seen in tunica vaginalis.
- Grade IV varicocele on left side.
- Indirect inguinal hernia on right side.

Clinical correlation / Followup suggested

DR. NITIN JAINHAV
DAIRD DNB

02/08/2018 11:04
e-mail : sodani@sampunadiagnostics.com- www.sampunadiagnostics.com

ANCHES : Indore • Ujjain • Dewas • Sanwer • Khandwa • Khargone • Badwani • Dhar • Mhow • Shujalpur



Oligospermia

How To Treat It The Right Way?

Central lab
Central India's First and Largest Super-speciality reference laboratory
For Feedback / Home Collection Call 786-99999-37 / 33

Charitable Centre-CC111

Name: ISHWAR SINGH TANWAR Age: 25 Years Sex: Male
Referred By: DR. ARPIT CHOPRA Received On: 13-Sep-2018 16:27
Drawn On: 12-Sep-2018 16:25 Print Date: 13-Sep-2018 14:43
Accession No.: 1809110664E

Parameter	Result	Unit	Biological Reference Interval
Physical Examination			
Quantity	3	ml	
Colour	Milky White		
Viscosity	Viscous		
Liquefaction Time	30		
Microscopic Examination			
Sperm Count	14	million/ml	12 - 16
Sperm Motility			
Grade 0 (Non-Motile)	30	%	0 - 40
Grade 1 (Sluggish)	30	%	60 - 100
Grade 2 (Fair)	10	%	60 - 100
Grade 3 (Good)	10	%	60 - 100
Grade 4 (Excellent)	80	%	
Morphologic Evaluation			
Normal Morphology	30	%	60 - 100
Abnormal Forms	30	%	15 - 40
Immature Forms	40	%	

Central lab
Central India's First and Largest Super-speciality reference laboratory
For Feedback / Home Collection Call 786-99999-37 / 33

Charitable Centre-CC111

Name: ISHWAR SINGH TANWAR Age: 25 Years Sex: Male
Referred By: DR. ARPIT CHOPRA Received On: 28-Aug-2018 14:49
Drawn On: 28-Aug-2018 14:36 Print Date: 29-Aug-2018 12:06
Accession No.: 19081115623

Parameter	Result	Unit	Biological Reference Interval
Physical Examination			
Quantity	1.5	ml	
Colour	Milky white		
Viscosity	Viscous		
Liquefaction Time	30		
Microscopic Examination			
Sperm Count	10	million/ml	12 - 16
Sperm Motility			
Grade 0 (Non-Motile)	80	%	0 - 40
Grade 1 (Sluggish)	10	%	60 - 100
Grade 2 (Fair)	10	%	60 - 100
Grade 3 (Good)	00	%	60 - 100
Grade 4 (Excellent)	00	%	
Morphologic Evaluation			
Normal Morphology	30	%	60 - 100
Abnormal Forms	30	%	15 - 40

MR. HARSHAL PATEL Age: 30 Years Sex: M
Referred By: DR. ARPIT CHOPRA Received On: 17-Sep-2018
Drawn On: 17-Sep-2018 10:44 Report Date: 20-Sep-2018
Accession No.: 160310332

DEPARTMENT OF CLINICAL PATHOLOGY SEMEN ROUTINE

Parameter Result Unit Biological Reference Interval

Physical Examination

Quantity 20 ml

Colour Milky White

Viscosity Viscous

Liquefaction Time 30

Microscopic Examination

Sperm Count 20 million/ml

Sperm Motility

Grade 0 (Non-Motile) 40 % 0 - 40

Grade 1 (Sluggish) 30 % 60 - 100

Grade 2 (Fair) 40 % 60 - 100

Grade 3 (Good) 10 % 60 - 100

Grade 4 (Excellent) 0 %

Morphologic Evaluation

Normal Morphology 30 % 60 - 100

Abnormal Forms 30 % 15 - 40

Immature Forms 40 %

MR. HARSHAL PATEL Age: 30 Years Sex: M
Referred By: DR. ARPIT CHOPRA Received On: 18-Oct-2018
Drawn On: 18-Oct-2018 11:00 Report Date: 20-Oct-2018
Accession No.: 160310332

DEPARTMENT OF CLINICAL PATHOLOGY SEMEN ROUTINE

Parameter Result Unit Biological Reference Interval

Physical Examination

Quantity 20 ml

Colour Milky White

Viscosity Viscous

Liquefaction Time 30

Microscopic Examination

Sperm Count 12 million/ml

Sperm Motility

Grade 0 (Non-Motile) 40 % 0 - 40

Grade 1 (Sluggish) 30 % 60 - 100

Grade 2 (Fair) 40 % 60 - 100

Grade 3 (Good) 10 % 60 - 100

Grade 4 (Excellent) 0 %

Morphologic Evaluation

Normal Morphology 30 % 60 - 100

Abnormal Forms 30 % 15 - 40

Immature Forms 40 %

MR. HARSHAL PATEL Age: 30 Years Sex: M
Referred By: DR. ARPIT CHOPRA Received On: 22-Sep-2018 14:13
Drawn On: 22-Sep-2018 14:13 Report Date: 20-Sep-2018
Accession No.: 160310332

DEPARTMENT OF CLINICAL PATHOLOGY SEMEN ROUTINE

Parameter Result Unit Biological Reference Interval

Physical Examination

Quantity 2.5 ml

Colour Milky White

Viscosity Viscous

Liquefaction Time 30

Microscopic Examination

Sperm Count 50 million/ml

Sperm Motility

Grade 0 (Non-Motile) 30 % 0 - 40

Grade 1 (Sluggish) 30 % 60 - 100

Grade 2 (Fair) 30 % 60 - 100

Grade 3 (Good) 10 % 60 - 100

Grade 4 (Excellent) 0 %

Morphologic Evaluation

Normal Morphology 30 % 60 - 100

Abnormal Forms 30 % 15 - 40

Immature Forms 40 %

MR. HARSHAL PATEL Age: 30 Years Sex: M
Referred By: DR. ARPIT CHOPRA Received On: 22-Sep-2018 11:21
Drawn On: 22-Sep-2018 11:21 Report Date: 20-Sep-2018
Accession No.: 160310332

DEPARTMENT OF CLINICAL PATHOLOGY SEMEN ROUTINE

Parameter Result Unit Biological Reference Interval

Physical Examination

Quantity 3.5 ml

Colour Milky White

Viscosity Viscous

Liquefaction Time 30

Microscopic Examination

Sperm Count 85 million/ml

Sperm Motility

Grade 0 (Non-Motile) 30 % 0 - 40

Grade 1 (Sluggish) 30 % 60 - 100

Grade 2 (Fair) 30 % 60 - 100

Grade 3 (Good) 10 % 60 - 100

Grade 4 (Excellent) 0 %

Morphologic Evaluation

Normal Morphology 30 % 60 - 100

Abnormal Forms 30 % 15 - 40

Immature Forms 40 %

MR. RAFIQUE PATEL Age: 30 Years Sex: M
Referred By: DR. PUNDIRKAR BHARAJA
Drawn On: 28-Jun-2016 11:08 Report Date: 28-Jun-2016
Accession No.: 160310332

DEPARTMENT OF CLINICAL PATHOLOGY SEMEN ROUTINE

Parameter Result Unit Biological Reference Interval

Physical Examination

Quantity 3.0 ml

Colour Milky white

Viscosity Viscous

Liquefaction Time 30

Microscopic Examination

Sperm Count 25 million/ml

Sperm Motility

Grade 0 (Non-Motile) 30 % 0 - 40

Grade 1 (Sluggish) 30 % 60 - 100

Grade 2 (Fair) 30 % 60 - 100

Grade 3 (Good) 10 % 60 - 100

Grade 4 (Excellent) 0 %

Morphologic Evaluation

Normal Morphology 30 % 60 - 100

Abnormal Forms 30 % 15 - 40

Immature Forms 40 %

MR. RAFIQUE PATEL Age: 30 Years Sex: M
Referred By: DR. ARPIT CHOPRA Received On: 12-Mar-2016 12:05
Drawn On: 12-Mar-2016 12:05 Report Date: 12-Mar-2016
Accession No.: 1603105032

DEPARTMENT OF CLINICAL PATHOLOGY SEMEN ROUTINE

Parameter Result Unit Biological Reference Interval

Physical Examination

Quantity 2.5 ml

Colour MILKY WHITE

Viscosity Viscous

Liquefaction Time 30

Microscopic Examination

Sperm Count 50 million/ml

Sperm Motility

Grade 0 (Non-Motile) 30 % 0 - 40

Grade 1 (Sluggish) 30 % 60 - 100

Grade 2 (Fair) 30 % 60 - 100

Grade 3 (Good) 10 % 60 - 100

Grade 4 (Excellent) 0 %

Morphologic Evaluation

Normal Morphology 30 % 60 - 100

Abnormal Forms 30 % 15 - 40

Immature Forms 40 %

MR. RAFIQUE PATEL Age: 30 Years Sex: M
Referred By: DR. ARPIT CHOPRA Received On: 12-Mar-2016 12:05
Drawn On: 12-Mar-2016 12:05 Report Date: 12-Mar-2016
Accession No.: 1603105032

DEPARTMENT OF CLINICAL PATHOLOGY SEMEN ROUTINE

Parameter Result Unit Biological Reference Interval

Physical Examination

Quantity 3.5 ml

Colour MILKY WHITE

Viscosity Viscous

Liquefaction Time 30

Microscopic Examination

Sperm Count 85 million/ml

Sperm Motility

Grade 0 (Non-Motile) 30 % 0 - 40

Grade 1 (Sluggish) 30 % 60 - 100

Grade 2 (Fair) 30 % 60 - 100

Grade 3 (Good) 10 % 60 - 100

Grade 4 (Excellent) 0 %

Morphologic Evaluation

Normal Morphology 30 % 60 - 100

Abnormal Forms 30 % 15 - 40

Immature Forms 40 %

MALE INFERTILITY
(AZOOSPERMIA / OLIGOSPERMIA)
CURED SUCCESSFULLY
BY MODERN HOMOEOPATHY
PRESCRIPTION LYCOPODIUM 0/0
BD Regards Aarogya Super Speciality
Modern Homoeopathic Clinic
(Computerised) Dr. Arpit Chopra
Homoeopathy & Critical case specialist)
102, Krishna Tower, Opposite
Curewell Hospital, Janjirwala
chouraha, New Palasia, Indore,
You may check cured patients
reports & feedbacks on Website-
www.homoeopathy.cure.com,
+91-9907527914, 9713092737

AAADHYA SUPER SPECIALITY NIGRAH HOMOEPATHIC CLINIC (Computerized)
Dr. Arpit Chopra (Jain)
PHYSICIAN (JAIN)
PHYSICIAN (JAIN)
PHYSICIAN (JAIN)

101, Sector 14, Gurgaon, Haryana
 Phone: 01299-233333, 01299-233334
 Email: info@aaadhyahomoeopathy.com

Handwritten notes and prescriptions in Hindi and English.

REPORT
USG WHOLE ABDOMEN

Real time sonography of WHOLE ABDOMEN shows:
RT KIDNEY: is normal in size and echotexture. Parenchyma is normal in thickness. Corticomedullary differentiation is clear. Pelvic collecting system is normal. No hydronephrosis seen. No renal calculi seen. Perinephric space is normal.
LT KIDNEY: is normal in size and echotexture. Parenchyma is normal in thickness. Corticomedullary differentiation is clear. Pelvic collecting system is normal. No hydronephrosis seen. No renal calculi seen. Perinephric space is normal.
BOTH KIDNEYS: are normal in size and echotexture. Parenchyma is normal in thickness. Corticomedullary differentiation is clear. Pelvic collecting system is normal. No hydronephrosis seen. No renal calculi seen. Perinephric space is normal.
BLADDER: is normal in size and echotexture. No calculi seen. No hydronephrosis seen. No renal calculi seen. Perinephric space is normal.
UTERUS: is normal in size and echotexture. No calculi seen. No hydronephrosis seen. No renal calculi seen. Perinephric space is normal.
OVARIES: are normal in size and echotexture. No calculi seen. No hydronephrosis seen. No renal calculi seen. Perinephric space is normal.

PREETI C.T. SCAN CENTRE
CT SCAN OF WHOLE ABDOMEN

Handwritten report detailing CT scan findings for the abdomen.

Bath Care **MediCar**

REPORT

Handwritten report with various fields and text.

Diagno LABS

Handwritten report from Diagno Labs.

X-RAY HOUSE & IMAGING CENTRE
Abdominal X-Ray

Handwritten report for an abdominal X-ray.

X-RAY HOUSE & IMAGING CENTRE
Abdominal X-Ray

Printed report for an abdominal X-ray with a signature.

PREETI C.T. SCAN CENTRE
CT SCAN OF WHOLE ABDOMEN

Handwritten report for a CT scan of the abdomen.

MANDISORE DIAGNOSTICS
CT Scan, X-Ray & Laboratory

Printed report for a CT scan from Mandisore Diagnostics.

PROSTATOMEGALY

Handwritten notes and diagrams related to prostate enlargement.

Handwritten notes and diagrams related to prostate enlargement.

Pre & Post Treatment Report

Before treatment
Treatment
After treatment

Handwritten report detailing treatment and results.

Handwritten report detailing treatment and results.

Lastic
Ultrasonography
REPORT

Handwritten report from Lastic Ultrasonography.

CHL-Hospitals
DEPARTMENT OF SONOGRAPHY
USG WHOLE ABDOMEN (MALE)

Printed report for an ultrasound of the whole abdomen from CHL-Hospitals.

CHL-Hospitals
DEPARTMENT OF SONOGRAPHY
USG WHOLE ABDOMEN (MALE)

Printed report for an ultrasound of the whole abdomen from CHL-Hospitals.



Oligospermia

How To Treat It The Right Way?

DEPARTMENT OF CLINICAL PATHOLOGY SEMEN ROUTINE

Patient Name: MR. RAJESH KUMAR
Ref By: DR. ANKIT CHOPRA
Accession No: 1500100001

Method of Collection: Masturbation
Liquefaction Time: 30 Min.

GENERAL EXAMINATION
Quantity: 2.5 ml
Colour: Milky white
Viscosity: Viscous
Liquefaction Time: 30

MICROSCOPIC EXAMINATION
Sperm Count: 50

Physical Examination
Quantity: 2.5
Colour: Milky white
Viscosity: Viscous
Liquefaction Time: 30

MICROSCOPIC EXAMINATION
Sperm Count: 50

DEPARTMENT OF CLINICAL PATHOLOGY SEMEN ROUTINE

Patient Name: MR. RAJESH KUMAR
Ref By: DR. ANKIT CHOPRA
Accession No: 1500100001

Method of Collection: Masturbation
Liquefaction Time: 30 Min.

GENERAL EXAMINATION
Quantity: 2.5 ml
Colour: Milky white
Viscosity: Viscous
Liquefaction Time: 30

MICROSCOPIC EXAMINATION
Sperm Count: 50

Physical Examination
Quantity: 2.5
Colour: Milky white
Viscosity: Viscous
Liquefaction Time: 30

MICROSCOPIC EXAMINATION
Sperm Count: 50

OLIGOSPERMIA (Male Infertility)

Dr. Ankit Chopra (MD)
M.D. (Sexual Medicine)
M.D. (Urology)

CURED

DEPARTMENT OF CLINICAL PATHOLOGY SEMEN ROUTINE

Patient Name: MR. RAJESH KUMAR
Ref By: DR. ANKIT CHOPRA
Accession No: 1500100001

Method of Collection: Masturbation
Liquefaction Time: 30 Min.

GENERAL EXAMINATION
Quantity: 2.5 ml
Colour: Milky white
Viscosity: Viscous
Liquefaction Time: 30

MICROSCOPIC EXAMINATION
Sperm Count: 50

Physical Examination
Quantity: 2.5
Colour: Milky white
Viscosity: Viscous
Liquefaction Time: 30

MICROSCOPIC EXAMINATION
Sperm Count: 50

CARE Medical Investigations PATHOLOGY

Patient Name: MR. RAJESH KUMAR
Ref By: DR. ANKIT CHOPRA
Accession No: 1500100001

Method of Collection: Masturbation
Liquefaction Time: 30 Min.

GENERAL EXAMINATION
Quantity: 2.5 ml
Colour: Milky white
Viscosity: Viscous
Liquefaction Time: 30

MICROSCOPIC EXAMINATION
Sperm Count: 50

Physical Examination
Quantity: 2.5
Colour: Milky white
Viscosity: Viscous
Liquefaction Time: 30

MICROSCOPIC EXAMINATION
Sperm Count: 50

CARE Medical Investigations PATHOLOGY

Patient Name: MR. RAJESH KUMAR
Ref By: DR. ANKIT CHOPRA
Accession No: 1500100001

Method of Collection: Masturbation
Liquefaction Time: 30 Min.

GENERAL EXAMINATION
Quantity: 2.5 ml
Colour: Milky white
Viscosity: Viscous
Liquefaction Time: 30

MICROSCOPIC EXAMINATION
Sperm Count: 50

Physical Examination
Quantity: 2.5
Colour: Milky white
Viscosity: Viscous
Liquefaction Time: 30

MICROSCOPIC EXAMINATION
Sperm Count: 50

DEPARTMENT OF CLINICAL PATHOLOGY SEMEN ROUTINE

Patient Name: MR. RAJESH KUMAR
Ref By: DR. ANKIT CHOPRA
Accession No: 1500100001

Method of Collection: Masturbation
Liquefaction Time: 30 Min.

GENERAL EXAMINATION
Quantity: 2.5 ml
Colour: Milky white
Viscosity: Viscous
Liquefaction Time: 30

MICROSCOPIC EXAMINATION
Sperm Count: 50

Physical Examination
Quantity: 2.5
Colour: Milky white
Viscosity: Viscous
Liquefaction Time: 30

MICROSCOPIC EXAMINATION
Sperm Count: 50

DEPARTMENT OF CLINICAL PATHOLOGY SEMEN ROUTINE

Patient Name: MR. RAJESH KUMAR
Ref By: DR. ANKIT CHOPRA
Accession No: 1500100001

Method of Collection: Masturbation
Liquefaction Time: 30 Min.

GENERAL EXAMINATION
Quantity: 2.5 ml
Colour: Milky white
Viscosity: Viscous
Liquefaction Time: 30

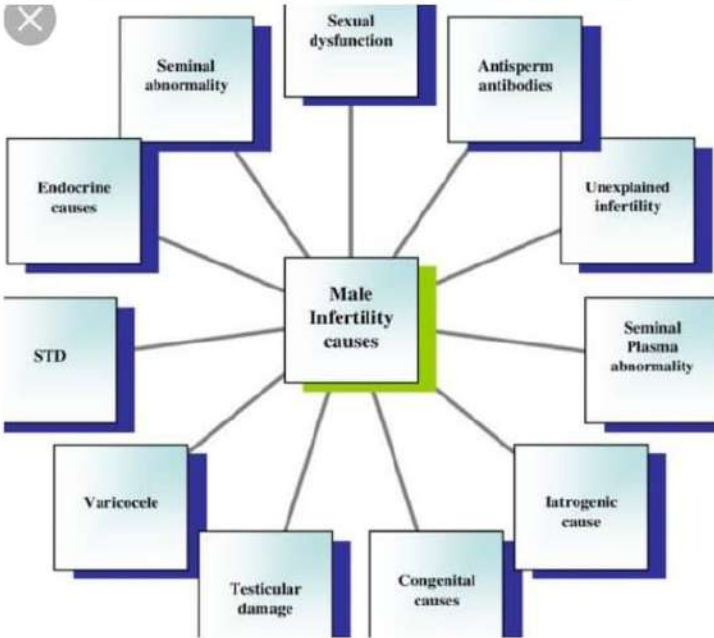
MICROSCOPIC EXAMINATION
Sperm Count: 50

Physical Examination
Quantity: 2.5
Colour: Milky white
Viscosity: Viscous
Liquefaction Time: 30

MICROSCOPIC EXAMINATION
Sperm Count: 50

08:27

08:27



1000 डी.डी. नाम उद्धर शर्मा
 1100 पता रोड नंबर 22 पाना
 1200 फोन. 9826237272
 1300 मुझे आरोग्य मार्ग लेने का
 1400 मोह था. आपने चौपड़ा की
 1500 इलाज से 15 दिन में ही प्रकाम मिली
 1600 मे गुणवत्ता बढ़े है आपने चौपड़ा
 1700 का उन्निर्ग मेरा इलाज कर मेरी
 1800 मदद की धन्यवाद है
 आपने चौपड़ा

Home

E-mail: manishmasatkar@gmail.com Mobile: 9329557676

Name: Manish Masatkar

Designation:

Date	Topic	Response
	I am prechymuch satisfied with the treatment I had. Its very good and giving instant result to the problem. I am thankful to Dr. Arpit Jain for the treatment he has provided.	

Contact Record Sexual Problems

Company: Dr. Arpit Jain

Address: 2157, 2158, 2159, 2160, 2161, 2162, 2163, 2164, 2165, 2166, 2167, 2168, 2169, 2170, 2171, 2172, 2173, 2174, 2175, 2176, 2177, 2178, 2179, 2180, 2181, 2182, 2183, 2184, 2185, 2186, 2187, 2188, 2189, 2190, 2191, 2192, 2193, 2194, 2195, 2196, 2197, 2198, 2199, 2200

Phone: 9329557676

Email: manishmasatkar@gmail.com

Name: Manish Masatkar

Designation:

Date	Topic	Response
	1) The clinic is good	
	2) All Dr. give advice in a friendly.	
	3) Treatment is good & permanent.	
	4) Excellent	

Dr. Arpit Jain
 MD (General Medicine)
 MD (Sexual Medicine)
 MD (Infertility)

Sexual Problems January 2016 Friday

22

Surgey: Prabhu Kishore

Phone: 7838715108

Email ID: SP 220570975

I was suffering from a problem about night fall. I am very second time to homopathy clinic. They doctor, Arpit Jain, treat me for my medicines. It was good result from me. I feel better.

Dr. Arpit Chopta (Jain)
 MD (General Medicine)
 MD (Sexual Medicine)
 MD (Infertility)

Sexual Problems Pavan Patidar (Jain)

Age: 35

Complaint: erectile dysfunction

Start Date: 15/01/2016

End Date:

Expected:

Objectives:

मेरे पारंपरिक कृत्रिम सहायक से erection problem से परेशान था किन्तु जब Dr. Arpit सर से treatment लिया तब से Natural erection ही शुरु हो गई।

Health management के लिये आप ही बेहतर treatment है।
Asogya Clinical

Acidity & Spermatorrhea January 2016 Tuesday

19

Dr. Arpit Jain

I am suffering from acidity and spermatorrhea. After I meet with Dr. Arpit Jain, I found that he has helped me in my problem. I am very happy and satisfied with his effective treatment.

Dr. Arpit Chopta (Jain)
 MD (General Medicine)
 MD (Sexual Medicine)
 MD (Infertility)

1000 डॉ. अरुण शर्मा, उम्र 35 वर्ष, फोन-9039308776

1100 मैं प्रीकमिलेरी लीन के बाह
 1200 लगभग 8 महीने तक पूरी कोशिशों
 1300 पर इलाज के बावजूद परिवार
 1400 अधूरा लगता था, क्योंकि मुझे
 1500 पहिले द्वारा गर्भ धारण में
 1600 मेरी कमियां के कारण दिक्कत
 1700 आ रही थी, काफ़ी सारा
 1800 इलाज करवाने के बाह ही
 1900 आपने चौपड़ा कर मेरी
 2000 साउजन होय्या मेरी 6 महीने
 2100 के सेवन से लगभग 1 महीने
 2200 बाह मेरी पहिले को सफलता
 2300 स्वक गर्भ उत्तर गया
 2400 डॉ. साठव ने मेरे परिवार
 2500 को पूरा कर हम सभी को

Before Treatment

Name: MR. RAFIQUE PATEL
 Ref. By: DR. PINDHARKAR SHAILAJA MD
 Consultant: DR. KOCHHAR KAPIL M.B.B.S., M.S.

Age/Sex: 23 Yr/M
 Date: 08/Dec/2015

SEMEN EXAMINATION

Method of Collection: Masturbation
 Liquefaction Time: 30 Min
 Semen Collection at: Lab
 Semen Preserved at: 37 Degree

GENERAL EXAMINATION

Quantity: 5.20 ml
 Appearance: Milky (w)

CHEMICAL EXAMINATION

Reaction: Alkaline
 Fructose Test: 0.5

Microscopic Examination

Sperm Count: Nil

After Treatment

Name: MR. RAFIQUE PATEL
 Referred By: DR. ARPIT CHOPRA
 Drawn On: 24-Jun-2016 11:08
 Accession No.: 1509109630

Age: 24 Years Sex: Male
 Received On: 24-Jun-2016 11:10
 Report Date: 24-Jun-2016

Parameter	Result	Unit	Biological Reference Interval
Physical Examination			
Quantity	3.6	ml	
Colour	Milky white		
Viscosity	Viscous		
Liquefaction Time	30		
Microscopic Examination			
Sperm Count	50	million/ml	50 - 150
Sperm Motility	95	%	0 - 40
Grade 0 (Non-Motile)	05	%	60 - 100
Grade 1 (Sluggish)	05	%	
Grade 2 (Fair)	05	%	
Grade 3 (Good)	05	%	
Grade 4 (Excellent)	05	%	

Before Treatment

Name: MR. VIVEK SHARMA
 Referred By: DR. ARPIT CHOPRA
 Drawn On: 12-Mar-2016 12:05
 Accession No.: 1603105032

Age: 32 Years Sex: Male
 Received On: 12-Mar-2016 12:06
 Report Date: 12-Mar-2016

Parameter	Result	Unit	Biological Reference Interval
Physical Examination			
Quantity	2.5	ml	
Colour	MILKY WHITE		
Viscosity	Viscous		
Liquefaction Time	30		
Microscopic Examination			
Sperm Count	50	million/ml	50 - 150

After Treatment

Name: MR. VIVEK SHARMA
 Referred By: DR. ARPIT CHOPRA
 Drawn On: 12-Mar-2016 12:05
 Accession No.: 1603105032

Age: 32 Years Sex: Male
 Received On: 12-Mar-2016 12:06
 Report Date: 12-Mar-2016

Parameter	Result	Unit	Biological Reference Interval
Physical Examination			
Quantity	3.5	ml	
Colour	MILKY WHITE		
Viscosity	Viscous		
Liquefaction Time	30		
Microscopic Examination			
Sperm Count	85	million/ml	50 - 150

Before treatment

Name: MR. MANISH MASATKAR
 Referred By: DR. ARPIT CHOPRA
 Drawn On: 08-Mar-2015 14:13
 Accession No.: 1503101080

Age: 31 Years Sex: Male
 Received On: 08-Mar-2015 14:15
 Report Date: 08-Mar-2015

Parameter	Result	Unit	Biological Reference Interval
Physical Examination			
Quantity	5.0	ml	
Colour	Milky White		
Viscosity	Viscous		
Liquefaction Time	30		
Microscopic Examination			
Sperm Count	10	million/ml	50 - 150

After treatment

Name: MR. MANISH MASATKAR
 Referred By: DR. ARPIT CHOPRA
 Drawn On: 22-Mar-2015 11:21
 Accession No.: 1503105280

Age: 31 Years Sex: Male
 Received On: 22-Mar-2015 11:22
 Report Date: 22-Mar-2015

Parameter	Result	Unit	Biological Reference Interval
Physical Examination			
Quantity	2.0	ml	
Colour	Milky White		
Viscosity	Viscous		
Liquefaction Time	40		
Microscopic Examination			
Sperm Count	50	million/ml	50 - 150

Before treatment

Name: MR. RONAK JAIN
 Referred By: ARPIT CHOPRA
 Drawn On: 02-Sep-2013 11:38
 Accession No.: 1309200144

Age: 23 Years Sex: Male
 Received On: 02-Sep-2013 11:43
 Report Date: 02-Sep-2013

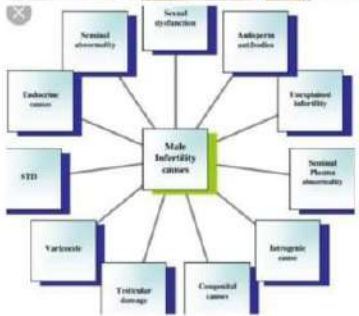Parameter	Result	Unit	Biological Reference Interval
Physical Examination			
Quantity	3.6	ml	
Colour	MILKY WHITE		
Viscosity	Viscous		
Liquefaction Time	45		
Microscopic Examination			
Sperm Count	48	million/ml	50 - 150

After treatment

Name: MR. RONAK JAIN
 Referred By: ARPIT CHOPRA
 Drawn On: 09-Oct-2013 13:01
 Accession No.: 1310201132

Age: 23 Years Sex: Male
 Received On: 09-Oct-2013 14:13
 Report Date: 09-Oct-2013

Parameter	Result	Unit	Biological Reference Interval
Physical Examination			
Quantity	1.5	ml	
Colour	MILKY WHITE		
Viscosity	Viscous		
Liquefaction Time	35		
Microscopic Examination			
Sperm Count	82	million/ml	50 - 150



Handwritten notes in Hindi, likely a patient history or treatment plan. The text is partially illegible but appears to discuss symptoms and medical advice.

Handwritten notes in Hindi, continuing the patient history or treatment plan. The text is partially illegible but appears to discuss symptoms and medical advice.

Handwritten notes in Hindi, continuing the patient history or treatment plan. The text is partially illegible but appears to discuss symptoms and medical advice.

Clinical Evolution

Before Treatment

Name: MR. HARSHAL PATIL
 Referred By: DR. ARPIT CHOPRA
 Drawn On: 17-Sep-2016 10:44
 Accession No.: 1609107614

Age: 32 Years Sex: Male
 Received On: 17-Sep-2016 10:44
 Report Date: 20-Sep-2016

Parameter	Result	Unit	Biological Reference Interval
Microscopic Examination			
Sperm Count	NO SPERMATOZOA SEEN	million/ml	50 - 150
Agglutination	Nil		
Fructose Test	Positive		

After Treatment

Name: MR. HARSHAL PATIL
 Referred By: DR. ARPIT CHOPRA
 Drawn On: 10-Oct-2016 10:02
 Accession No.: 1610104131

Age: 32 Years Sex: Male
 Received On: 10-Oct-2016 10:02
 Report Date: 16-Oct-2016

Parameter	Result	Unit	Biological Reference Interval
Microscopic Examination			
Sperm Count	85	million/ml	50 - 150
Sperm Motility			
Grade 0 (Non-Motile)	10	%	0 - 40
Grade 1 (Sluggish)	30	%	60 - 100
Grade 2 (Fair)	40	%	60 - 100
Grade 3 (Good)	10	%	60 - 100
Grade 4 (Excellent)	10	%	

Handwritten notes in Hindi, likely a patient history or treatment plan. The text is partially illegible but appears to discuss symptoms and medical advice.

Handwritten notes in Hindi, continuing the patient history or treatment plan. The text is partially illegible but appears to discuss symptoms and medical advice.

Dr. Arpit Chopra (Jain)
 M.D. HOMOEOPATHY
 (Critical & Surgical Diseases Specialist)

9907527914, 9713037
 9713092737, 79999978

AAROGYA SUPER SPECIALITY MODERN HOMOEOPATHIC CLINIC

Complete, Easy, Safe, Fast & Cost-effective

CAUSES OF OLIGOSPERMIA



मॉडर्न होम्यो

Modern Homeopathy - Complete, Permanent, Easy, Safe, Fast



Arpit Chopra (Jain) (MD) HOMEOPATHY
& SURGICAL DISEASE SPECIALIST
of Super Speciality Modern Homeopathy

AAROGYA SUPERSPECIALITY MODERN HOMEOPATHY
 Complete, Safe, Fast & Cost-Effective Permanent Modern Homeopathy
 Phone : 0731-4977076, Mobile : 97130-92737, 97130-92737

...e, Homoeopathic Preventive & Prophylaxis, Tetanus, Allergy, S...

Name : MR. VIVEK SHARMA **Age:** 32 Years
Referred By : DR. ARPIT CHOPRA **Received On :**
Drawn On : 12-Mar-2016 12:05 **Report Date :**
Accession No.: 1603105032



DEPARTMENT OF CLINICAL PATHOLOGY SEMEN ROUTINE			
Parameter	Result	Unit	Biological
Physical Examination			
Quantity	2.5	ml.	
Colour	MILKY WHITE		
Viscosity	Viscous		
Liquification Time	30		
Microscopic Examination			
Sperm Count	50	million/ml	50 - 150

after treatment

DEPARTMENT OF CLINICAL PATHOLOGY SEMEN ROUTINE			
Parameter	Result	Unit	Biolog
Physical Examination			
Quantity	3.5	ml.	
Colour	MILKY WHITE		
Viscosity	Viscous		
Liquification Time	30		
Microscopic Examination			
Sperm Count	85	million/ml	50 - 15

Before treatment

Parameter	Result	Unit	Biological Reference Interval
Physical Examination			
Quantity	2.5	ml.	
Colour	MILKY WHITE		
Viscosity	Viscous		
Liquification Time	30		
Microscopic Examination			
Sperm Count	50	million/ml	50 - 150

After treatment

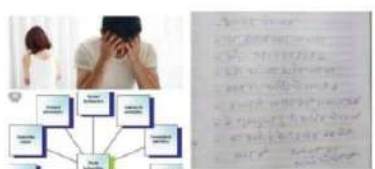Parameter	Result	Unit	Biological Reference Interval
Physical Examination			
Quantity	3.5	ml.	
Colour	MILKY WHITE		
Viscosity	Viscous		
Liquification Time	30		
Microscopic Examination			
Sperm Count	85	million/ml	50 - 150

Before treatment

Parameter	Result	Unit	Biological Reference Interval
Physical Examination			
Quantity	2.5	ml.	
Colour	MILKY WHITE		
Viscosity	Viscous		
Liquification Time	30		
Microscopic Examination			
Sperm Count	50	million/ml	50 - 150

After treatment

Parameter	Result	Unit	Biological Reference Interval
Physical Examination			
Quantity	3.5	ml.	
Colour	MILKY WHITE		
Viscosity	Viscous		
Liquification Time	30		
Microscopic Examination			
Sperm Count	85	million/ml	50 - 150



Clinical Evolution

Name : MR. HARSHAL PATIL **Age:** 30 Years **Sex :** M
Referred By : DR. ARPIT CHOPRA **Received On :** 11-Sep-2016
Drawn On : 11-Sep-2016 09:44 **Report Date :** 11-Sep-2016
Accession No.: 1603107014

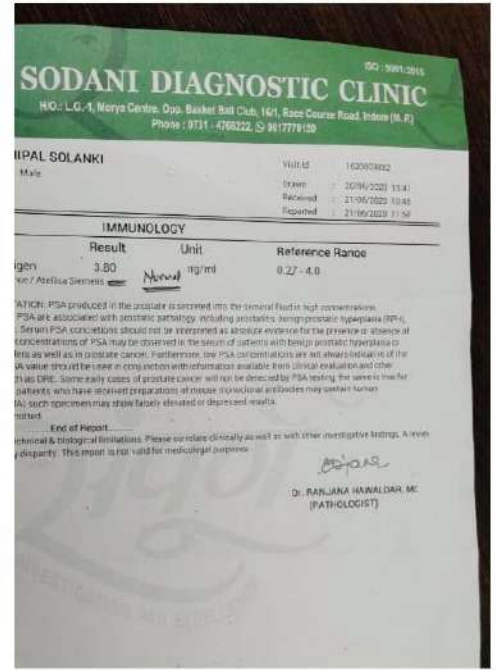
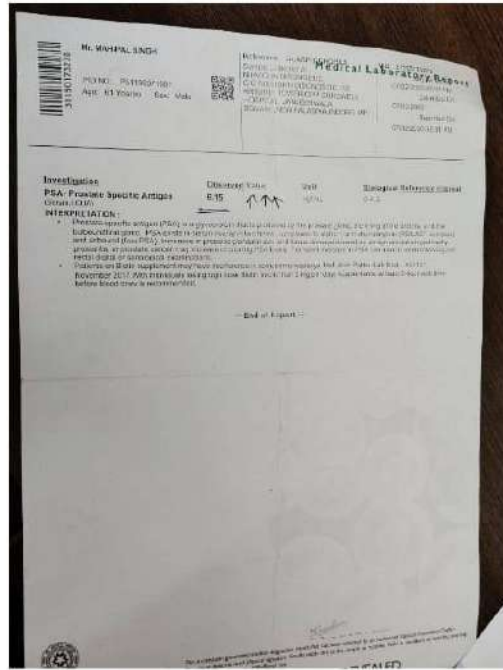Parameter	Result	Unit	Biological Reference Interval
Physical Examination			
Quantity	2.5	ml.	
Colour	MILKY WHITE		
Viscosity	Viscous		
Liquification Time	30		
Microscopic Examination			
Sperm Count	50	million/ml	50 - 150

Dr. Arpit Chopra (Jain)
M.D. HOMEOPATHY
 (Critical & Surgical Diseases Specialist)

AAROGYA SUPERSPECIALITY MODERN HOMEOPATHIC CLINIC

9907527914, 9713037
 9713092737, 7999978

Everything you need to know about ENLARGED PROSTATE



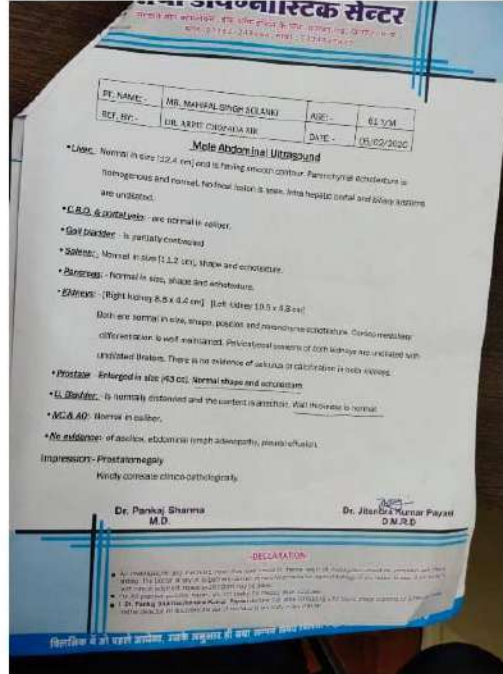
Men 55 to 69 years old should make individual decisions about being screened for prostate cancer with a PSA test.

Early diagnosis can help catch the cancer before it becomes life-threatening or causes serious symptoms.

Recent research has shown that deaths from prostate cancer have decreased by 30% since the PSA test became available.

What Is the PSA Test?

Screening for prostate cancer begins with a prostate specific antigen (PSA) test that measures the level of PSA in the blood.



पेशाबिटी मॉडर्न होम्योपैथिक क्लीनिक

पता : 102, प्रथम मंजूर, कुरावेल हॉस्पिटल, जंजीरवाला चौराहा, न्यू कुरावेल

सुबह : 10 से दोप. 3 बजे तक, शाम : 5 से 10 बजे तक

रविवार सुबह : 12 से दोप. 3 बजे तक

7737 7914 0

www.aarogyamodernhomoeopathy.com

Email : arpitchopra23@gmail.com, aarogyamodernhomoeopathy@gmail.com

मे. महिपाल सिंह सोलंकी 61, M, Date 09/07/2020

Address: Khargapur, Mob: 9926976048, Ref. No. 12

Complaint: A Prostate trouble, PSA - 6.15

History: H/O HTN, allopathic medicine use 2 1/2 years.

Suspected Prostate Cancer with PSA High 6.15 ng/ml Before Treatment After Modern Homoeopathy Treat CURED

09 Thursday Raised PSA Level 020 JULY

मेरानाग महिपाल सिंह सोलंकी को खरगपुर में आया है।
 उसे प्रोस्टेट कैंसर के इलाज के लिए आया है।
 इससे पहले 3 साल तक एडोपेक्टिन इलाज करवाया था। उसके कुछ ही फलक गहरी पस आखीर के बाद के साने इसे आप्रशक की-सलादी-फेने काद के होको पेकी इलाज की डाक्टर अरपीत जैन सा।
 से लीया मुझे 75 पली इलाज की मीठ होगया है इसके लीये डाक्टर (सा. का) के इलाज (सा. का) के इलाज का इलाज महिपाल सिंह सोलंकी खरगपुर से मो.नं. 9926976048



COMPLETE CURE, EASY, SAFE, FAST & COST EFFECTIVE

आरोग्य

HOMOEOPATHY

Dr. Arpit Chopra (Jain)
 M.D. HOMOEOPATHY
 (Critical & Surgical Diseases Specialist)

9907527914, 971303 9713092737, 799997

AAROGYA SUPER SPECIALITY MODERN HOMOEOPATHIC CLINIC

Complete, Easy, Safe, Fast & Costeffective
 Permanent Modern Homoeopathy Cure With Advance Lifestyle
 102, First Floor Krishna Tower In front of Curawell Hospital
 Janjeer Waia Churaha, INDORE (M.P.)
 Time : 10 am to 3pm & 5 pm to 10 pm, Sunday : 12.00 am to 2.00 pm
 Please Take Appointment Before Consultancy as Possible, Ph. 0731-4977
 www.homoeopathy.cure.in, Email - arpitchopra23@gmail.com

KRAT CLINIC
 Tower, Near RSEB Office, Udaipur
 444

"कर्म ब्रह्मो, वेदी ब्रह्मो"
 अधिकायन में सधुर्वीर्य करे
 पूजा विधि परीक्षण का समय उचित अर्थात् है।

Name : Mr. Anil Sharma
 Age/Sex : 56 /M
 By :
 Date : 29-Jan-20

ULTRASOUND STUDY OF KUB

KIDNEYS : Both kidneys are normal in size, shape and echotexture. Renal parenchyma appears normal. No evidence of hydronephrosis, calculus of cortical scarring is seen in either kidney.
 Right kidney measures : 10.9 x 4.9 cms.
 Left kidney measures : 11.4 x 5.2 cms.

URINARY BLADDER : Urinary bladder is well distended and appears normal in contour. The wall thickness appears normal.
 Pre void: 200 cc. Post void: 35 cc.

PROSTATE : Prostate is enlarged and heterogeneous in echotexture. It measures 4.9 x 4.7 x 4.2 cms. Volume: 50 cc.

Dr Lal PathLabs

Lab: D-4, Mathura, Opp. General Post Office, Near Chandra Clinic, Udaipur - 313001
 Mo. +91 98290 91144-91145-91146-91147-91148-91149-91150-91151-91152-91153-91154-91155-91156-91157-91158-91159-91160
 Regd. Office/National Reference Lab: Dr. Lal PathLabs Ltd., Block E, Sector-18, Rohini, New Delhi - 110005
 Home Care: +91 22 2554 1000 Fax: +91 22 2554 1001 PMS-5000 Fax: +91 11 2386 2134
 E-mail: customer@drallpathlabs.com Web: www.drallpathlabs.com
 CIN No. U74901DL1999PLC005382

ID: 284990529
 NAME: MR. ANIL SHARMA
 REF. BY: SELF
 AGE: 56 YRS SEX: M
 DATE: 20.06.2020

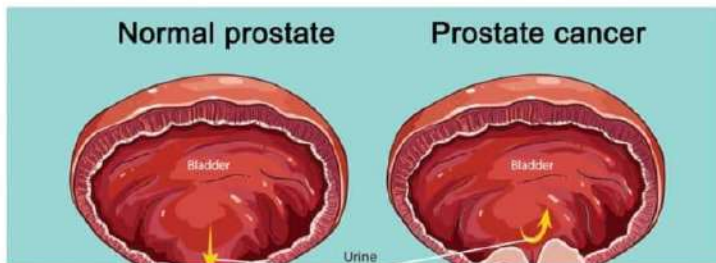
ULTRASOUND STUDY OF KUB

RIGHT KIDNEY : Right kidney is normal in size, shape & echotexture. Renal parenchyma appears normal. No evidence of hydronephrosis, calculus or cortical scarring is seen. Right kidney measures 112 x 53 mm.

LEFT KIDNEY : Left kidney is normal in size, shape & echotexture. Renal parenchyma appears normal. No evidence of hydronephrosis, calculus or cortical scarring is seen. Left kidney measures 109 x 48 mm.

URINARY BLADDER : Urinary bladder is well distended and appears normal in contour. The wall thickness appears normal. Lumen is clear.
 Pre void : 130 cc Postvoid : Nil.

PROSTATE : Prostate is enlarged in size. It measures 37 x 38 x 38 mm. Vol. 28 cc.
 No free fluid is seen in the pelvis.



Prostate cancer

Also called: prostatic carcinoma

OVERVIEW SYMPTOMS TREATMENTS NEWS

Dr Lal PathLabs

Regd. Office/National Reference Lab: Dr. Lal PathLabs Ltd., Block E, Sector-18, Rohini, New Delhi - 110005
 Tel: +91 11 3024 4133, 2989 5050, Fax: +91 11 2386 2134, E-mail: depathlab@drallpathlab.com
 Web: www.drallpathlabs.com, CIN No. U74901DL1999PLC005382

L29 - WALK IN HIRAN MAGRE LAB
 GROUND FLOOR, 1-TA-25 & 1-TA-13, RHB COLONY SEC-5, HIRAN MAGRI UDAIPUR

Name : Mr. ANIL SHARMA
 Lab No. : 273839381 Age: 56 Years Gender: Male
 A/c Status : P Ref By : Dr. DR.ANKIT AGARWAL
 Collected : 13/3/2020 8:31:00AM
 Received : 13/3/2020 8:33:13AM
 Reported : 13/3/2020 12:59:21PM
 Report Status : Final

Test Name	Results	Units	Bio. Ref. Interval
CREATININE, SERUM (Compensated Jaffe's reaction, IDMS traceable)	1.10	mg/dL	0.70 - 1.20
ALT (SGPT), SERUM (IFCC)	28	U/L	<41.00
PSA (PROSTATE SPECIFIC ANTIGEN), TOTAL, SERUM (ECLIA)	11.490	ng/mL	<3.10

Note

- This is a recommended test for detection of prostate cancer along with Digital Rectal Examination (DRE) in males above 50 years of age
- False negative / positive results are observed in patients receiving mouse monoclonal antibodies for diagnosis or therapy
- PSA levels may appear consistently elevated / depressed due to the interference by heterophilic antibodies & nonspecific protein binding
- Immediate PSA testing following digital rectal examination, ejaculation, prostatic massage, indwelling catheterization, ultrasonography and needle biopsy of prostate is not recommended as they falsely elevate levels
- PSA values measured at least should not be interpreted as absolute evidence of the presence or

Dr Lal PathLabs

Regd. Office/National Reference Lab: Dr. Lal PathLabs Ltd., Block E, Sector-18, Rohini, New Delhi - 110005
 Tel: +91 11 3024 4133, 2989 5050, Fax: +91 11 2386 2134, E-mail: depathlab@drallpathlab.com
 Web: www.drallpathlabs.com, CIN No. U74901DL1999PLC005382

575 - Walk in Udaipur Lab

Name : Mr. ANIL SHARMA
 Lab No. : 281551020 Age: 56 Years Gender: Male
 A/c Status : P Ref By : SELF
 Collected : 26/3/2020 7:14:00AM
 Received : 26/3/2020 7:19:34AM
 Reported : 26/3/2020 10:30:29AM
 Report Status : Final

Test Name	Results	Units	Bio. Ref. Interval
CREATININE, SERUM (Compensated Jaffe's reaction, IDMS traceable)	0.81	mg/dL	0.70 - 1.20
ALT (SGPT), SERUM (IFCC)	20	U/L	<41.00
PSA (PROSTATE SPECIFIC ANTIGEN), TOTAL, SERUM (ECLIA)	2.610	ng/mL	<3.10

Note

- This is a recommended test for detection of prostate cancer along with Digital Rectal Examination (DRE) in males above 50 years of age
- False negative / positive results are observed in patients receiving mouse monoclonal antibodies for diagnosis or therapy
- PSA levels may appear consistently elevated / depressed due to the interference by heterophilic antibodies & nonspecific protein binding
- Immediate PSA testing following digital rectal examination, ejaculation, prostatic massage, indwelling catheterization, ultrasonography and needle biopsy of prostate is not recommended as they falsely elevate levels
- PSA values measured at least should not be interpreted as absolute evidence of the presence or

Dr. Arpit Chopra (Jain)
 M.D. HOMOEOPATHY
 (Critical & Surgical Diseases Specialist)

आरोग्य
 COMPLETE CURE, EASY, SAFE, FAST & COST EFFECTIVE
 MODERN HOMOEOPATHY

9907527914, 9713037
 9713092737, 79999978

AAROGYA SUPER SPECIALITY MODERN HOMOEOPATHIC CLINIC

Male infertility

1. Genetic Disorder

2. Alcohol, Tobacco Consumption

3. Exposure to Radiation

4. Exposure to Radiation

5. Injury to the groin area

6. Exposure to Poisonous Chemicals

7. Hormone Imbalance

Name : MR. MANISH MASATKAR Age : 31 Years Sex : Male
 Referred By : DR. ARPIT CHOPRA Received On : 08-Mar-2015 14:15
 Drawn On : 08-Mar-2015 14:13 Before treatment Report Date : 08-Mar-2015
 Accession No.: 1503101680

DEPARTMENT OF CLINICAL PATHOLOGY
SEMEN ROUTINE

Parameter	Result	Unit	Biological Reference Interval
Physical Examination			
Quantity	5.0	ml.	Before Modern Homeopathy Treatment
Colour	Milky White		
Viscosity	Viscous		
Liquefaction Time	30		
Microscopic Examination			
Sperm Count	10	million/ml	50 - 150

Dr.Arpit Chopra (Jain) (MD) HOMEOPATHY
 CRITICAL & SURGICAL DISEASE SPECIALIST
 Inventor Of Super Speciality Modern Homeopathy

AAROGYA SUPERSPECIALITY MODERN HOMEOPATHIC CLINIC
 Complete, Safe, Fast & Cost-Effective Permanent Modern Homeopathy Cure with Advanced Lifestyle
 Phone : 0731-4977076, Mobile : 97130-92737, 97130-37737, 79999-78894, 99075-27914

Infertility, Impotency, Sexualdiseases, Rheumatism, Backache, Sciatica, Migraine, KneePain, Dial

Name : MR. MANISH MASATKAR Age : 31 Years Sex : Male
 Referred By : DR. ARPIT CHOPRA Received On : 22-Mar-2015 17:21
 Drawn On : 22-Mar-2015 17:13 Report Date : 22-Mar-2015

DEPARTMENT OF CLINICAL PATHOLOGY
SEMEN ROUTINE

Parameter	Result	Unit	Biological Reference Interval
Physical Examination			
Quantity	2.5	ml.	After 15 days Modern Homeopathy Treatment
Colour	Milky White		
Viscosity	Viscous		
Liquefaction Time	45		
Microscopic Examination			
Sperm Count	40	million/ml	50 - 150
Sperm Motility	40	%	0 - 40
Grade 1 (Progressive)	15	%	00 - 100
Grade 2 (Fast)	25	%	00 - 100
Grade 3 (Slow)	30	%	00 - 100
Grade 4 (Immotile)	10	%	00 - 100

Dr.Arpit Chopra (Jain) (MD) HOMEOPATHY
 CRITICAL & SURGICAL DISEASE SPECIALIST
 Inventor Of Super Speciality Modern Homeopathy

AAROGYA SUPERSPECIALITY MODERN HOMEOPATHIC CLINIC
 Complete, Safe, Fast & Cost-Effective Permanent Modern Homeopathy Cure with Advanced Lifestyle
 Phone : 0731-4977076, Mobile : 97130-92737, 97130-37737, 79999-78894, 99075-27914

Infertility, Impotency, Sexualdiseases, Rheumatism, Backache, Sciatica, Migraine, KneePain, Dial, Breast Tumor & Uterine Fibroid, Prostate & Urological Diseases, Renal & Gallbladder Stone, I

Name : MR. MANISH MASATKAR Age : 31 Years Sex : Male
 Referred By : DR. ARPIT CHOPRA Received On : 16-May-2015 08:28
 Drawn On : 16-May-2015 08:28 Report Date : 16-May-2015

DEPARTMENT OF CLINICAL PATHOLOGY
SEMEN ROUTINE

Parameter	Result	Unit	Biological Reference Interval
Physical Examination			
Quantity	6.5	ml.	After 2 Months Of Modern Homeopathy Treatment
Colour	MILKY WHITE		
Viscosity	Viscous		
Liquefaction Time	45		
Microscopic Examination			
Sperm Count	110	million/ml	50 - 150
Sperm Motility	10	%	0 - 40
Grade 1 (Progressive)	20	%	00 - 100
Grade 2 (Fast)	30	%	00 - 100
Grade 3 (Slow)	30	%	00 - 100
Grade 4 (Immotile)	10	%	00 - 100



Dr. Arpit Chopra (Jain) (MD) HOMEOPATHY
 (Critical & Surgical Diseases Specialist)

9907527914, 9713037737, 9713092737, 79999978

AAROGYA SUPER SPECIALITY MODERN HOMEOPATHIC CLINIC

Complete, Easy, Safe, Fast & Costeffective
 Permanent Modern Homeopathy Cure With Advance Lifestyle
 102, First Floor Krishna Tower In front of Curewell Hospital
 Janjeer Wala Churaha, INDORE (M.P.)
 Time : 10 am to 3pm & 5 pm to 10 pm, Sunday : 12.00 am to 2.00 pm
 Please Take Appointment Before Consultancy as Possible, Ph.: 0731-4977076
 www.homoepathycure.com, Email - arpitchopra23@gmail.com

aarogyahomoeopathyindore.com

मॉडर्न होम्योपैथी
 Complete, Permanent, Easy, Safe, Fast & Cost Effective



AAROGYA SUPERSPECIALITY MODERN HOMEOPATHIC CLINIC
 Complete, Safe, Fast & Cost-Effective Permanent Modern Homeopathy Cure with Advanced Lifestyle
 Phone : 0731-4977076, Mobile : 97130-92737, 97130-37737, 79999-78894, 99075-27914



डॉ. अर्पित चोपड़ा (जैन)
एम. डी. होम्योपैथी
जटिल, अस्पताल एवं
शल्य रोग विशेषज्ञ

आरोग्य सुपर स्पेशलिटी मॉडर्न होम्योपैथिक क्लीनिक



कम्पलिट * परमानेंट * ईजी * सेफ * फास्ट एण्ड कॉस्ट इफैक्टिव

* कैंसर * किडनी फेलियर * अस्पताल में गंभीर रूप से भर्ती मरिजों का उपचार * कोमा *
* शल्य चिकित्सा योग्य रोग * आँटो इम्यून रोग * जीवनभर दवाई लेने वाले रोगों की रोकथाम
एवं 300 प्रकार के असाध्य जटिल रोगों की चिकित्सा।

102, 104, प्रथम मंजिल, कृष्णा टॉवर, क्योरवेल हॉस्पिटल के सामने, जंजीरवाला चौराहा, न्यू पलासिया, इन्दौर (म.प्र.)

फोन : 0731-4977076, मो. : 97130-92737, 97130-37737, 79999-78894, 99075-27914

www.homoepathycure.in www.aarogyahomeopathyindore.com Email : arpitcho23@gmail.com



Dr. Gandhi and Daughter's Clinic

Gandhi Diagnostic Clinic

83, Shrinagar Main Road, Opp. Bima Nagar, INDORE (M.P.)

Antosh M. Gandhi, DMRD (Sonologist) • Reg. No. 7414 (M.P.) • Mobile : 93294-39448

DATE - 21/10/2020

PATIENT - MR. PRAFUL PANDAY

AGE / SEX - 57 YRS / M

REFD. BY - DR. ARPIT CHOPDA (JAIN) M.D. HOMOEOPATHY INDORE

WHOLE ABDOMEN ULTRASONOGRAPHY REPORT (PRINT)

Liver is normal in size, shape and echotexture is normal // No IHBD.
No focal lesion seen in liver // Hepatic surface is smooth.

Gall bladder is normal in size and shape and echotexture. No calculi seen in gall bladder.
Gall bladder wall thickness is normal.

Spleen is normal in size, shape and echotexture.
Pancreas is normal in size, shape and echotexture.

Both kidneys are normal in size and shape and echotexture.

The renal outline are smooth & regular, the cortical thickness is adequate and
The Parenchyma is normal in echotexture.

Right kidney :- 104 x 40 mm. // Left kidney :- 96 x 50 mm.

No calculi / No calyceal dilatation seen in both kidneys.

Both ureters are undilated.

Prostate is enlarged in size and shape and echotexture is subtle altered - BPH,
And prostate is 7-8 mm size small cystic area is visible - S/O of Enlarged prostate.

Median lobe is mildly prominent. // Prostate size - 44 x 43 x 38 mm. (WEIGHT - 32.0 gms.)

Urinary bladder is normal in size and contour And wall trabeculations are mildly prominent.

PVR IS 150 ml. // No free fluid seen in abdomen.

IMPRESSION :- LIVER, SPLEEN, PANCREAS BOTH KIDNEYS ARE NORMAL

:- ENLARGED PROSTATE // MEDIAN LOBE IS MILDLY PROMINENT.

:- BLADDER CYSTITIS

AP



Gandhi Diagnostic Clinic

83, Shrinagar Main Road, Opp. Bima Nagar, INDORE (M.P.)

Antosh M. Gandhi, DMRD (Sonologist) • Reg. No. 7414 (M.P.) • Mobile : 93294-39448

DATE - 21/11/2020

PATIENT - MR. PRAFULL PANDAY

AGE / SEX - 57 YRS / M

REFD. BY - DR. ARPIT CHOPDA (JAIN)

INDORE

WHOLE ABDOMEN ULTRASONOGRAPHY REPORT (PRINT)

Liver is normal in size, shape and echotexture is NORMAL. // No IHBD.
No focal lesion seen in liver. // Hepatic surface is smooth.

Gall bladder is normal in size and shape and echotexture. // No calculi seen in gall bladder.
Gall bladder wall thickness is normal.

Spleen is normal in size, shape and echotexture.
Pancreas is normal in size, shape and echotexture.

Both kidneys are normal in size and shape and echotexture.

Right kidney :- 104 x 40 mm. // Left kidney :- 96 x 50 mm.

The renal outline are smooth & regular, the cortical thickness is adequate and
The Parenchyma is normal in echotexture.

No calculi / No calyceal dilatation seen in both kidneys.

Both ureters are undilated.

Prostate is enlarged in size and shape and echotexture is subtle Altered.

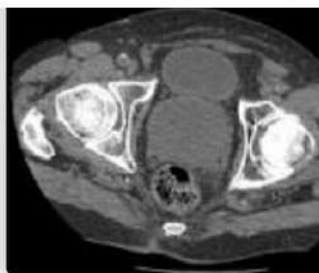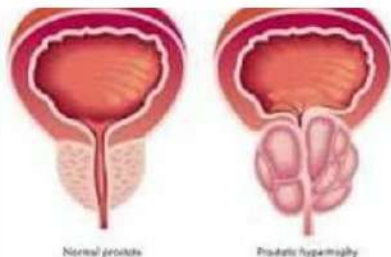
Prostate size - 44 x 42 x 35 mm. (Weight - 26.27 gms.)

In Prostate 7-8 mm size small cystic area is visible

Median lobe is mildly prominent

Urinary bladder is normal in size and contour. // No calculi seen in Urinary bladder.

PVR is 20 ml. // No free fluid seen in abdomen.



Prostatomegaly is a term used to generally describe enlargement of the prostate gland from whatever cause.

आरोग्य सुपर स्पेशलिटी मॉडर्न होम्योपैथिक क्लीनिक

डॉ. अर्पित चोपड़ा (जैन)

9406853406

MODERN HOMOEOPATHY

शल्य रोग एवं असाध्य रोग विशेषज्ञ

Reg. No. 14367

फोन : 0731-4977076

मोबाइल : 97130-92737, 97130-37737,

79999-78894, 99075-27914

वेबसाइट : www.homoepathycure.com / in

www.aarogyahomeopathyindore.com



पता : 102, प्रथम मंजिल
कृष्णा टॉवर, क्योरवेल हॉस्पिटल के सामने
जंजीरवाला चौराहा, न्यू पलासिया, इन्दौर

सुबह : 10 से दोपहर 3 बजे तक, शाम : 5 से 10 बजे तक
शुक्रवार सुबह : 12 से दोपहर 3 बजे तक

Email : arpitcho23@gmail.com
aarogyamodernhomeopathy@gmail.com

Complete, Easy, Safe, Fast
Post-effective Permanent
Modern Homoeopathy Cure
Advanced Lifestyle

Name: Prafull Pandey Age: 57 Sex: M Date: 21/10/20

Address: Indore Mob: Ref. No.

Prostatomegaly
Bladder
Cystitis
Whole Abdomen



डॉ. अर्पित चोपड़ा (जैन)
एम डी होम्योपैथी
जटिल, अस्पताल एवं
हान्य रोग विशेषज्ञ

आरोग्य सुपर स्पेशलिटी मॉडर्न होम्योपैथिक क्लीनिक



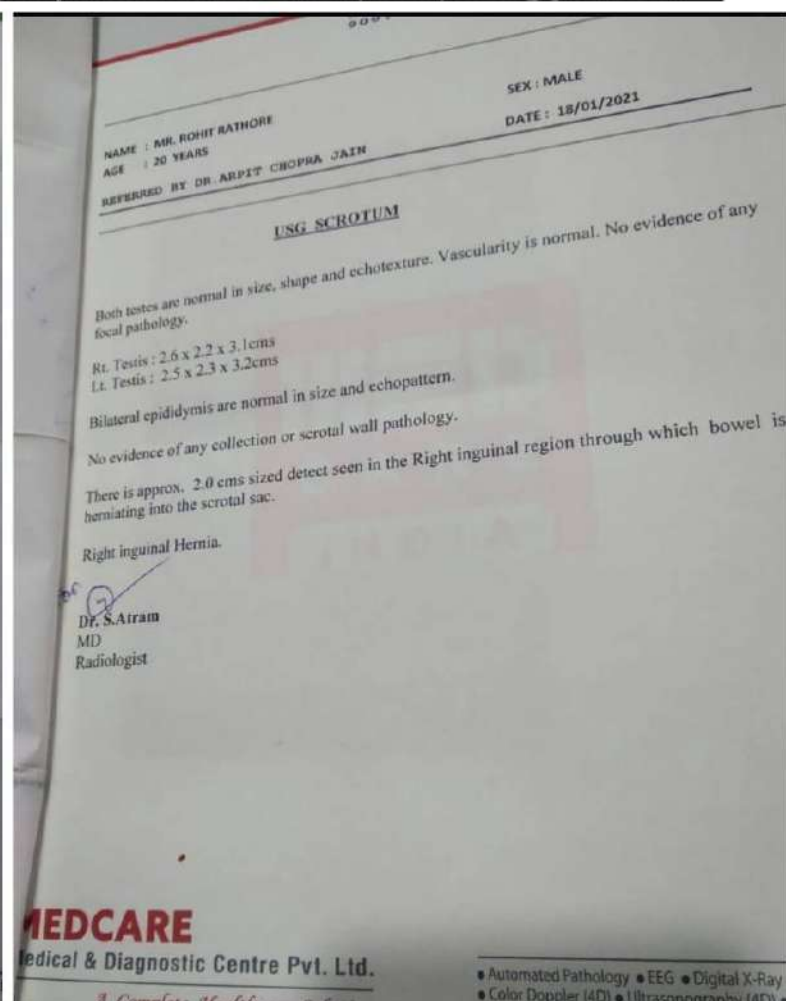
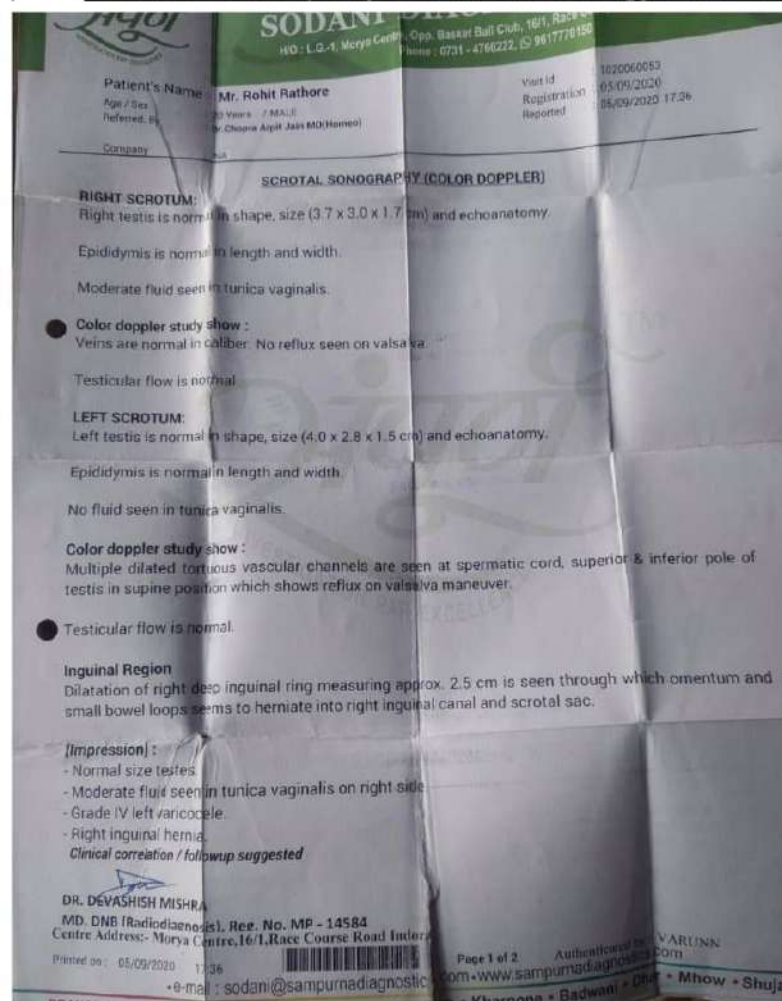
कम्पलिट * परमानेंट * ईजी * सेफ * फास्ट एण्ड कॉस्ट इफैक्टिव

* कैंसर * किडनी फेलियर * अस्पताल में गंभीर रूप से भर्ती मरिजों का उपचार * कोमा *
* शल्य चिकित्सा योग्य रोग * आँटो इम्यून रोग * जीवनभर दवाई लेने वाले रोगो की रोकथाम
एवं 300 प्रकार के असाध्य जटिल रोगों की चिकित्सा ।

102, 104, प्रथम मंजिल, कृष्णा टॉवर, क्योरवेल हॉस्पिटल के सामने, जंजीरवाला चौराहा, न्यू पलासिया, इन्दौर (म.प्र.)

फोन : 0731-4977076, मो. : 97130-92737, 97130-37737, 79999-78894, 99075-27914

www.homoeopathy cure.in, www.aarogyahomoeopathyindore.com Email : arpitchopra23@gmail.com



Varicocele

Also called: scrotum varicose veins

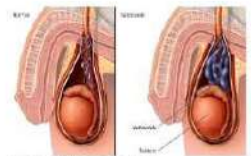
OVERVIEW SYMPTOMS TREATMENTS NEWS

An enlargement of the veins within the scrotum.

A varicocele may develop as a result of poorly functioning valves that are normally found in

A varicocele (VAR-ih-koe-seel) is an enlargement of the veins within the loose bag of skin that holds your testicles (scrotum). A varicocele is similar to a varicose vein you might see in your leg.

Varicoceles are a common cause of low sperm



Varicocele

Penis's disease

Caused by penile fibrosis

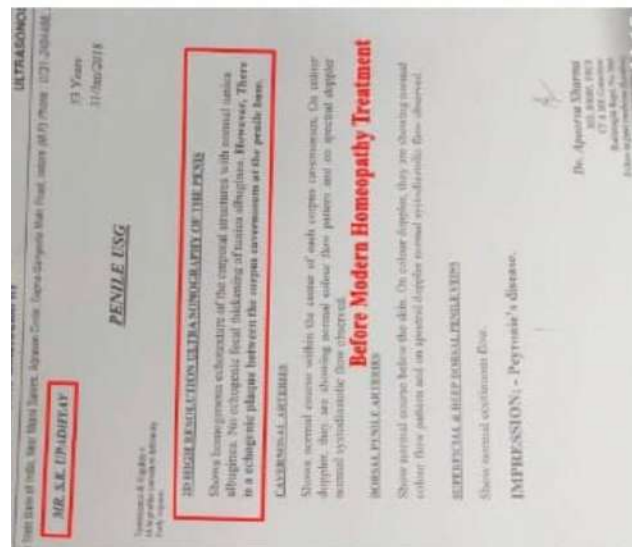

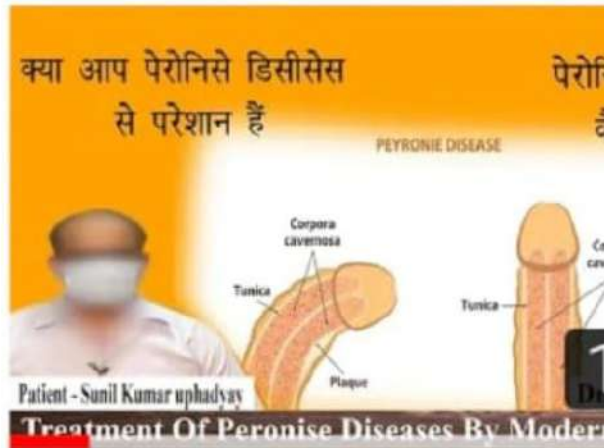
View

Symptoms

Treatments

Scar tissue inside the penis that causes painful erections.

Penis's disease is caused by repeated penile



कैंसर, किडनी फेलियर, अस्पताल में गंभीर रूप से भर्ती मरिजों का उपचार, कोमा, शल्य चिकित्सा योग्य रोग, ऑटो इम्यून रोग, जीवनभर दवाई लेने वाले रोगों की रोकथाम एवं 300 प्रकार के असाध्य जटिल रोगों की चिकित्सा ।

आरोग्य सुपर स्पेशलिटी मॉडर्न होमियोपैथी
कम्पलिट, परमानेंट, ईजी, सेफ, फास्ट एण्ड कॉस्ट इफैक्टिव
प्रथम मंजिल, कृष्णा टॉवर, कयोखेल हॉस्पिटल के सामने, जंजीरवाला चौराहा, न्यू पलासिया, इन्दौर
99075 27914 संपर्क : 0731-4977076, 79999 78894
homoeopathy.cure.in, www.aarogyahomeopathyindore.com Email : arpitchopra23@gmail.com

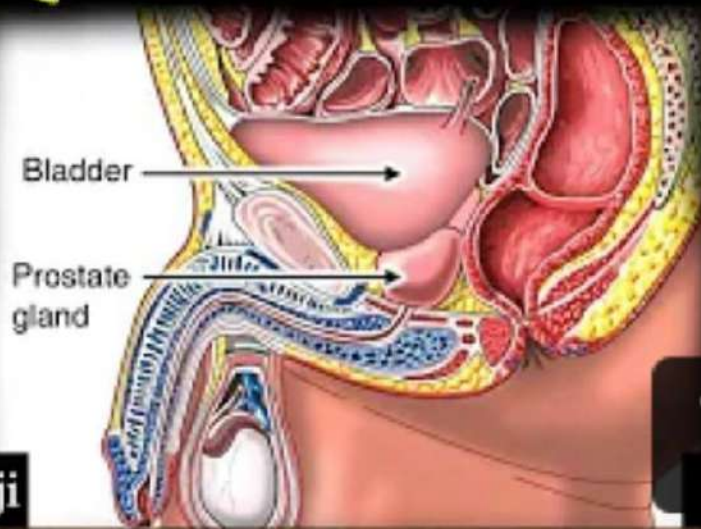
क्या आप प्रोस्टेट से परेशान हैं



क्या आप प्रोस्टेट को खत्म करना चाहते हैं

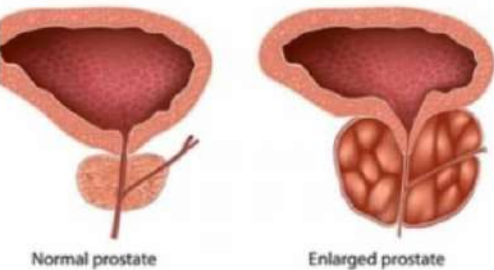


Patient - Thakur Singh Ji

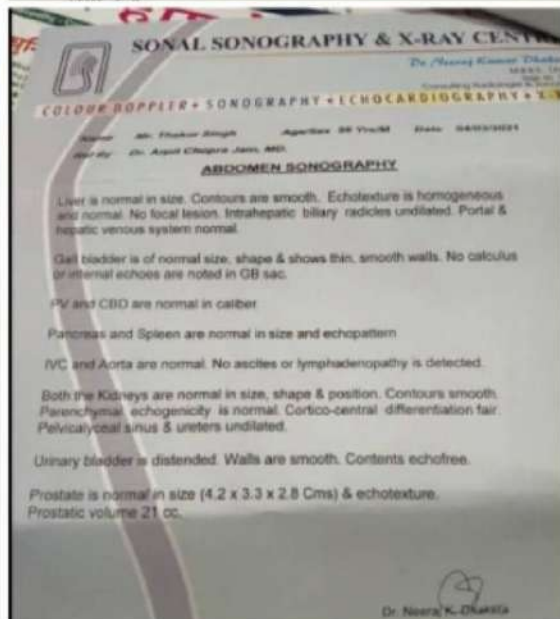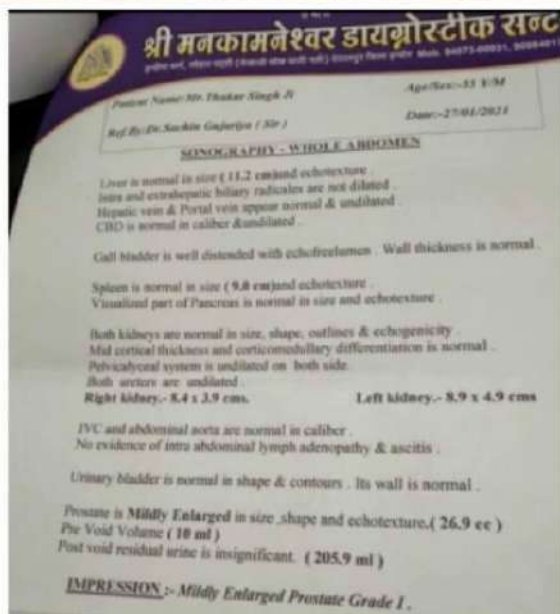


15:08
Dr. Arpit Chopra Jain

Benign Prostatic Hyperplasia



This gland secretes a fluid that protects the sperm. During ejaculation, this gland gets contracted and through its fluid enters into the urethra. An enlargement in this gland is called as Prostatomegaly. It usually



Handwritten notes in Hindi, including the name 'Dr. Arpit Chopra (Jain)' and 'ARMOVA SUPER SPECIALITY MODERN HOMEOPATHIC CLINIC'. The notes discuss the patient's condition and treatment.

आरोग्य सुपर स्पेशलिटी मॉडर्न होमियोपैथिक क्लिनिक

कमलित * परमानेंट * ईजी * सैफ * फास्ट एण्ड कॉस्ट इफेक्टिव

* कैन्सर * किडनी फेलियर * अल्पाताल में जंभीर रूप से भर्ती मरीजों का उपचार * कोमा * शल्य चिकित्सा योग्य रोग * आर्टो इन्फ्यूजन रोग * जीवनभर दर्दार्द लेने वाले रोगों की चिकित्सा * एवं 300 प्रकार के अस्वास्थ्य जटिल रोगों की चिकित्सा।

102/104, प्रथम मंजिल, कृष्णा टॉवर, बजोरवेल हॉस्पिटल के सामने, जंजीरवाला चौराहा, न्यू पलासिया, इन्डौर (म.प्र.)
फोन : 0731-4977076, मो. : 97130-92737, 97130-37737, 79999-78894, 99075-27914

www.homeopathy.cure.in, www.aarogyahomeopathyindore.com Email : arpitchohra23@gmail.com



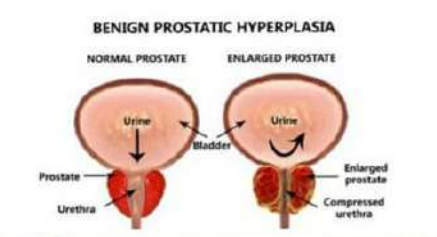


Benign prostate enlargement
 Also called: BPH

OVERVIEW SYMPTOMS TREATMENTS NEWS

Age-associated prostate gland enlargement that can cause urination difficulty.

This type of prostate enlargement isn't thought to be a precursor to prostate cancer.



Rishabh Diagnostics
 53, Puga Road, Bangalore, Karnataka, India
 Ph: 91 9845446227, 9845446228

NAME: ARVIND BHATT SRY DATE: 31.7.20
 REFERRED BY: DR. ARPI CHOPRA MS

USG WHOLE ABDOMEN

LIVER: is normal in size, shape and echotexture. No focal mass or diffuse lesion seen. IHR are not dilated. Portal vein normal.

GALL BLADDER: is normally distended, wall appears smooth and regular. No calculi and focal lesion seen. Pericholecystic areas normal.

PANCREAS: Pancreas is normal in size, shape and echogenicity. No focal and diffuse lesion seen. pancreatic duct is not dilated.

SPLEEN: is normal in size, shape and echotexture. Parenchyma is homogeneous. No focal or diffuse lesion seen.

BOTH KIDNEY: are normal in shape size and echogenicity. Pelvic system normal in thickness. Corticomedullary differentiation is clear. peripelvic system is normal. No hydronephrosis or renal calculus seen. Perirenal areas normal. Both ureter are not dilated. R.K. 4.4x3.7x2.5 CMs, L.K. 4.8x3.2x2 CMs.

AORTA AND IVC: are normal.

BLADDER: well distended, wall thickness normal, no evidence of any calculus and mass lesion seen. Post void: 220ml, post void: 140ml.

PROSTATE: is enlarged in size (approx. VOl: 25.3CC), shape and echogenicity. No focal and mass lesion seen.

NO perineal effusion, ascites or free fluid seen.

BOTH ILLAC FOSSA: Normal, no focal mass lesion seen.

IMPRESSION - ENLARGED PROSTATE WITH SIGNIFICANT POST VOID URINE.

Rishabh Diagnostics
 53, Puga Road, Bangalore, Karnataka, India
 Ph: 91 9845446227, 9845446228

NAME: ARVIND BHATT SRY DATE: 1.10.20
 REFERRED BY: DR. ARPI CHOPRA MS

USG WHOLE ABDOMEN

LIVER: is normal in size, shape and echotexture. No focal mass or diffuse lesion seen. IHR are not dilated. Portal vein normal.

GALL BLADDER: is well distended, wall appears smooth and regular. No calculi and focal lesion seen. Pericholecystic areas normal.

PANCREAS: Pancreas is normal in size, shape and echogenicity. No focal and diffuse lesion seen. pancreatic duct is not dilated.

SPLEEN: is normal in size, shape and echotexture. Parenchyma is homogeneous. No focal or diffuse lesion seen. Spleen size appears normal.

BOTH KIDNEY: are normal in shape size and echogenicity. Parenchyma is normal in thickness. Corticomedullary differentiation is clear. peripelvic system is compact. No hydronephrosis or renal calculus seen. Perirenal areas normal. Both ureter are not dilated. R.K. 3.0x3.5x2.0 CMs, L.K. 3.0x3.5x2.0 CMs.

AORTA AND IVC: are normal.

BLADDER: well distended, wall thickness normal, no evidence of any calculus and mass lesion seen.

PROSTATE: is enlarged in size (approx. VOl: 25.3CC), shape and echogenicity. No focal and mass lesion seen.

NO perineal effusion, ascites or free fluid seen.

BOTH ILLAC FOSSA: Normal, no focal mass lesion seen.



IMPRESSION - FATTY LIVER GRADE I, ENLARGED PROSTATE.

DR. ARPIT CHOPRA (JAIN)
 M.D. Homoeopathy
 101, First Floor, Rishabh, Near
 Puga Road, Bangalore, Karnataka, India
 Ph: 9845446227, 9845446228

Dr. Arpit Chandra - 09/10/20
 Radiation
 MHN - 3 years
 DM - 2 years
 Enlarged prostate
 in 20 days - 10
 - Diabetes
 - frequency of micturition
 - no burning sensation

Dr. Arpit Chopra (Jain)
 M.D. HOMOEOPATHY
 (Critical & Surgical Diseases Specialist)

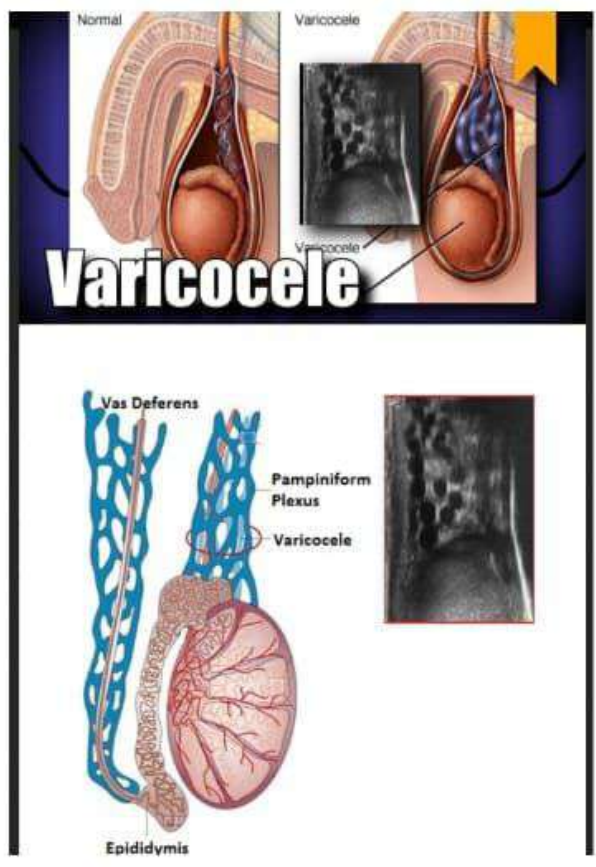
© 9907522914, 9713815277
 9713092237, 79999978



मॉडर्न होम्योपैथी
 Modern Homeopathy - Complete, Permanent, Easy, Safe, Fast & Cost Effective

GIRISH KUMAR

Dr. Arpit Chopra (MD) Homeopathy
 AAROGYA SUPERSPECIALTY MODERN HOMEOPATHIC CLINIC
 Complete, Safe, Fast & Cost-Effective Permanent Modern Homeopathy Care with Advanced Test Kit
 Phone: 0731-4977076, Mobile: 97130-92737, 97130-37737, 99975-74954, 99075-27914



Varicocele

Also called: scrotum varicose veins

Overview Symptoms Treatments

An enlargement of the veins within the scrotum.

A varicocele may develop as a result of poorly functioning valves that are normally found in veins. In other cases, it may occur from compression of a vein by a nearby structure.

कैंसर, किडनी फेलियर, अस्पताल में गंभीर रूप से भर्ती मरिजों का उपचार, कोमा, शल्य चिकित्सा योग्य रोग, ऑटो इम्यून रोग, जीवनभर दवाई लेने वाले रोगों की रोकथाम एवं 300 प्रकार के असाध्य जटिल रोगों की चिकित्सा।

आरोग्य सुपर स्पेशलिटी माईन होमियोपैथी
 कम्पलिट, परमानेंट, ईजी, सेफ, फास्ट एण्ड कॉस्ट इफैक्टिव

102, प्रथम मंजिल, कृष्ण टॉवर, वयोस्वेल हॉस्पिटल के सामने, जंजीराला पौराहा, न्यू पलारिया, इन्दौर म.प्र.
 99075 27914 संपर्क : 0731-4977076, 79999 78694
 www.homeopathycure.in, www.aarogyahomeopathyindore.com, Email : arpitchohra23@gmail.com

कैंसर, किडनी फेलियर, अस्पताल में गंभीर रूप से भर्ती मरिजों का उपचार, कोमा, शल्य चिकित्सा योग्य रोग, ऑटो इम्यून रोग, जीवनभर दवाई लेने वाले रोगों की रोकथाम एवं 300 प्रकार के असाध्य जटिल रोगों की चिकित्सा ।



आरोग्य सुपर स्पेशलिटी मॉडर्न होमियोपैथी

कम्पलिट, परमानेन्ट, ईजी, सेफ, फास्ट एण्ड कॉस्ट इफैक्टिव

102, प्रथम मंजिल, कृष्णा टॉवर, क्योरवेल हॉस्पिटल के सामने, जंजीरवाला चौराहा, न्यू पलासिया, इन्दौर म.प्र.

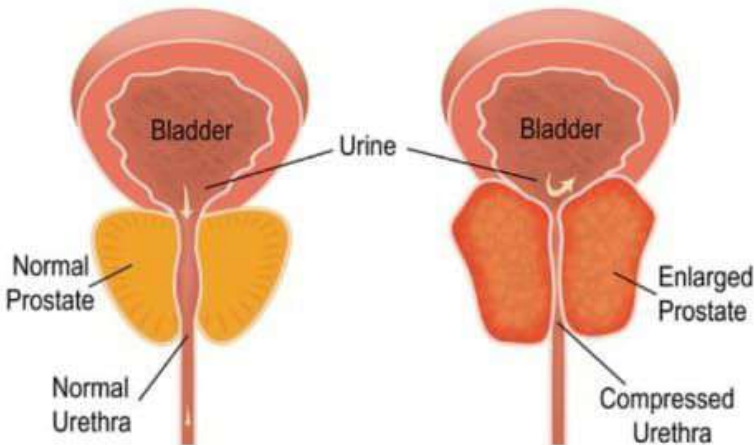
📞 99075 27914 संपर्क : 0731-4977076, 79999 78894

www.homoeopathycure.in, www.aarogyahomoeopathyindore.com Email : arpitchopra23@gmail.com

BENIGN PROSTATIC HYPERPLASIA

NORMAL PROSTATE

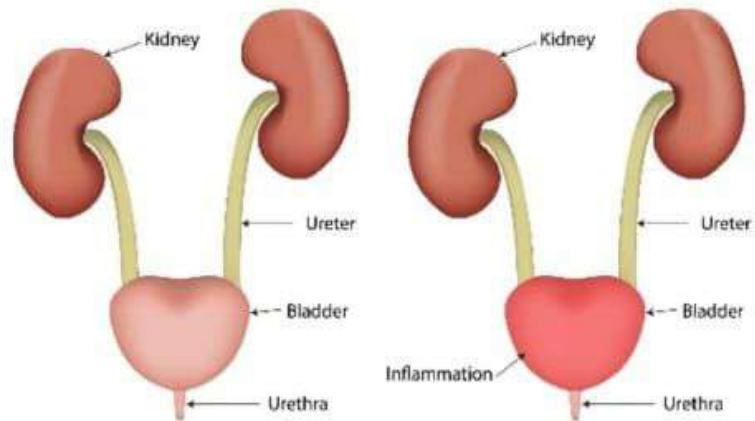
ENLARGED PROSTATE



Cystitis

Normal

Cystitis

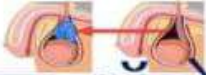

7 Benign Prostatic Hyperplasia & Cystitis (BPH) AUGUST 2022
 DUESDAY - AUGUST 19/8/22
 मे सुरेश बालोपिया इन्दौर निवासी।
 मे पिछले पिछले 3-4 वर्ष से मुझे इन्फेक्शन
 से परेशान था। काफी समय से इलाज
 किया। किन्तु बिमारी ठीक नहीं हो सकी।
 और मैं डॉ. के आदेशों का करूँ।
 इसी दौरान मुझे डॉ. अर्पित जी चौधरी
 का, इलाज की जानकारी मिली, जहाँ
 डॉ. के मिलने के बाद मुझे आदेशों
 कि सफल रही थी, और उनके
 समय पर ही इलाज किया। आपके
 आशुवादन में आप इन्फेक्शन रोकने में
 मेरा सही इलाज है।
 धन्यवाद डॉ. जी।
 धन्यवाद होमियोपैथी दवाई
 सुरेश बालोपिया
 इन्दौर

Dr. Arpit Chopra (Jain)
 M.D. HOMOEOPATHY
 (Clinical & Surgical) Disease Specialist
 AAROGYA SUPER SPECIALITY MODERN HOMOEOPATHIC CLINIC
 Contact: 9907527914, 9713077737, 7999978894

वैरीकोसिल

गुप्तांग में तकलीफ महसूस करना



बिना ऑपरेशन
सफल ईलाज



Dr Arpit Chopra (Jain)

Varicocele

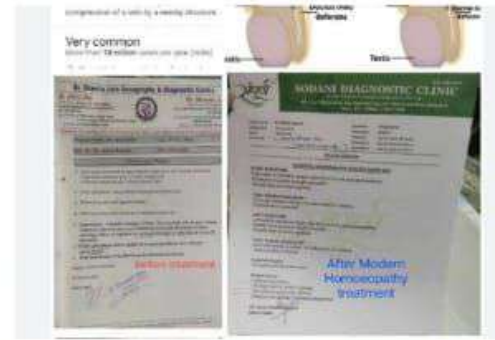Also called: scrotum varicose veins

An enlargement of the veins within the scrotum.

A varicocele may develop as a result of poorly functioning valves that are normally found in veins. In other cases, it may occur from compression of a vein by a nearby structure.

Very common

More than 10 million cases per year (India)



DURGA DIAGNOSTICS

DR. NAMITA DIVEKAR
M.B.D.M.R.D. (Mum.)
Consulting Sonologist

C/101, Gulamhar Complex Phase - II, By Post Road, Near Sanyal Hotel, VIKAR (W), Dist. Thane - 401 303
Tel: 0220 - 2505845 / 2504795 / 2507986. Mob: 9323125314 / 9730879863 / 9324151032

TIMINGS : Morning : 7 A.M. to Night : 10 P.M. (Emergency & Sunday: Please Call)

• Sonography • Color Doppler • Pathology

After Dr Arpit
Chopra Jain Modern
Homeopathy

Examination: - SONOGRAPHY OF SCROTUM (COLOR DOPPLER)

Best time, 15 mins, grey scale and color Doppler sonography of the scrotum was performed using the 7-10 MHz convex probe.

Scanning of the scrotum revealed the testis to be normal in size with homogeneous echotexture.

The Epididymis measures 32 X 28 X 21 mm and shows normal echotexture. The Vas deferens measures 30 X 29 X 21 mm and shows normal echotexture.

Unilateral epididymitis are normal. Both testis show normal vascularity.


There is no size free fluid in the Testis vagina. The median raphe of the scrotum is normal.

A 2 mm subcutaneous lipoma noted in the right scrotal skin. The spermatic vessels are normal. No size vascularity on present scan.

IMPRESSION :- Normal size of the testis. A 2 mm subcutaneous lipoma noted in the right scrotal skin. There is no size testicular torsion / hydrocele on present scan.

04.08.2023 Dr. Namita Divekar Sonologist

4/8/23
10 - Varicocele : 1 yrs
- B/L Grade II, III (4/8/23)
- Pain ⊕⊕
- Straining during micturition
- A small echogenic area scrotal wall, inf. to Rt. testis ? Lipoma (4/8/23) * 19x16



Before Treatment

YouTube surgery by Dr Arpit Chopra J...

YouTube VARICOCELE | Varicocele Su...

VARICOCELE वैरीकोसेल
Cure By Dr Arpit Chopra J...

कैंसर, किडनी फेलियर, अस्पताल में गंभीर रूप से भर्ती मरिजों का उपचार, कोमा, शल्य चिकित्सा योग्य रोग, ऑटो इम्यून रोग, जीवनभर दवाई लेने वाले रोगो की रोकथाम एवं 300 प्रकार के असाध्य जटिल रोगों की चिकित्सा ।



डॉ. अर्पित चौपडा (जैन)
एम. डी. होम्योपैथी
जटिल, असाध्य एवं
शल्य रोग विशेषज्ञ

आरोग्य सुपर स्पेशलिटी मॉडर्न होमियोपैथी

कम्पलिट, परमानेन्ट, ईजी, सेफ, फास्ट एण्ड कॉस्ट इफैक्टिव

102, प्रथम मंजिल, कृष्णा टॉवर, क्योरवेल हॉस्पिटल के सामने, जंजीरवाला चौराहा, न्यू पलासिया, इन्दौर म.प्र.

📞 99075 27914 संपर्क : 0731-4977076, 79999 78894

www.homoeopathy cure.in. www.aarogyahomoeopathyindore.com Email : arpitchopra23@gmail.com

EXRI XRAY HOUSE & IMAGING CENTER
Radiology Diagnostics
30 Slice CT Scan | Digital Mammography | Digital X-ray | Digital X-ray Angiogram | Color Doppler | 3D-4D Ultrasound
Liver Breast Ultrasonography | Central Ultrasound | Image Guided Stereotaxic | EBScanography | EGD | Pathology

237, Anoop Nagar, Agra Bombay Road, Nr. LG Circle, Indore (M.R.) | Ph.: 0731-4291159 | Mobile : +91 9109101525

Reg. No:	D40923-035	Date:	04/Sep/2023
PL Name:	MR. IRFAN SHAIKH	Age/Sex:	32 Yrs /M
Ref. By:	DR ARPIT CHOPRA JAIN MD HOMEO		

COLOUR DOPPLER OF SCROTUM

Both testes are small in size, shape and position. They have regular margins and normal echotexture. No calcification or focal lesion.

Right testis measures - 3.6 x 1.6 x 2.3cm. Vol - 7.0ml.
Left testis measures - 3.6 x 1.6 x 2.2cm. Vol - 6.8ml.

Both testes reveal normal Vascularity on doppler.

There is moderate right varicocele. Venous diameter - 3.3mm. Reflux on valsalva noted in supine position.

There is moderate left varicocele. Venous diameter - 3.2mm. Reflux on valsalva noted in supine position.

No free fluid seen in scrotal sac.

IMPRESSION:
Both testes are small.
Bilateral moderate varicoceles with reflux on both sides.

Before Treatment

DR. RAJENDRA BHANDARI
M.B.B.S, M.D (RadioDiagnosis)
Director
General & Breast Radiologist

DR. GAURAV BHANDARI
M.B.B.S, M.S, D.M.B (RadioDiagnosis)
Fellowship in Body Imaging (CT & MRI), SDOM, Mumbai
Asst. Professor RadioDiagnosis, MAMMC, Indore
Reg. No. MP-14591

DR. JALPA BHANDARI
M.B.B.S, MD (RadioDiagnosis)
Sr. Consultant, P.D. Hospital, Indore
Sr. Consultant, P.D. Hospital, Indore
Sr. Consultant, P.D. Hospital, Indore
Sr. Consultant, P.D. Hospital, Indore
Reg. No. MP-15432

THE BIOPSY
A Complete Diagnostic & Tissue Pathology Laboratory
An ISO 9001:2015 Certified Organization

NAME	IRFAN SHEIKH	AGE / SEX	32YM / M	OPD
REF. BY:	DR ARPIT CHOPRA MD	DATE	08 DEC 2023	

USG - SCROTUM

USG of scrotum was performed using high resolution linear probe.

Imaging Findings:
Bilateral testes are normal in shape & echotexture. No focal lesion seen.

The both testes are measuring approximately:
Right testis: 3.6 x 1.9 x 2.6 cm, volume-9.6 cm³
Left testis: 4.1 x 1.6 x 2.9 cm, volume-10.2 cm³

Right Epididymis: 1.1 x 0.8 cm.
Left Epididymis: 1.2 x 0.9 cm.

Both testes appear normal, slight asymmetry is appreciated in terms of size and volume of both testes, left being larger.

Bilateral caput epididymis appears normal.
Bilateral spermatic cord appears normal.

Few dilated and tortuous vessels are seen along bilateral inguinal channel along the emergence of scrotal vein. Few of them are extending up to superior pole of testis. Reflux is elicited on performing Valsalva maneuver and on standing position. No reflux is seen at rest. The varicosities measure up to approx. 0.31 cm on right and 0.32 cm on left on supine position.

Normal sonomorphology of scrotal skin is seen.

Impression:
Both testes appear normal, slightly asymmetric in terms of size and volume, left being larger.

Few dilated and tortuous vessels are along bilateral inguinal extending up to superior pole of testis showing reflux on Valsalva. No reflux at rest. The varicosities measure up to approx. 0.31 cm on right and 0.32 cm on left on supine position. Suggestive of mild early bilateral grade II varicocele.

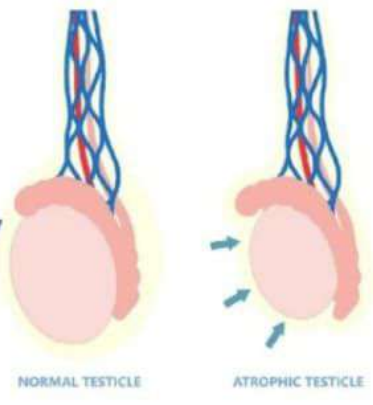
DR. RAJESH KUMAR GUPTA
DMS, DMRE, MRAPCS, MSOBR
Sr. Consultant, Cross-sectional Clinical Radiology (CT & MR) and Interventions

DR. AAYUSH MUNDRA
MBBS, DMRE
Junior Consultant & Scientific Officer

Transcribed by: VM

आरोग्य सुपर स्पेशलिटी का MRI डिपार्टमेंट : 0731-2990807, 9285208222
📞 0731-4970807, 4070807 | 📞 +91-928-527-9808 | Time: 8 AM to 8 PM | Email: mri@thebiopsy.in
28 & 21, सहाय नगर, केनर बीच के उत्तर, बीकानेर एक्स, इन्दौरा रोड, कन्दोले चौक के पास, इन्दौर

Explain Testicular Atrophy



What is Testicular Atrophy?

Testicular Atrophy

Healthy vs **Atrophy**

What is Testicular Atrophy?

prostate Dr Arpit Chopra...

ऑपरेशन या सर्जरी के बगैर पाए अपनी समस्याओं का इलाज

5:45

DR ARPIT CHOPRA JAIN

किसी प्रकार की सर्जरी या ऑपरेशन से बचाएगा ये वीडियो

5:53

DR ARPIT CHOPRA JAIN

कैंसर * किडनी फेलियर * अस्पताल में गैंगीर रूप से मर्ती गरिजों का उपचार * कोजा * शल्य चिकित्सा योग्य रोग * आंठो इन्फ्यूजन रोग * जीवनभर दवाई लेने वाले रोगों की रोकथाम एवं 300 प्रकार के असाध्य जटिल रोगों की चिकित्सा

आरोग्य सुपर स्पेशलिटी मॉडर्न होम्योपैथिक वलीनिक

कम्पलिट * परमानेंट * ईजी * सेफ * फास्ट एण्ड कॉस्ट इफेक्टिव

102, प्रथम मील, कुमाय टावर, इन्दौर हायवे के चपरे, इन्दौर काजवा, नू कान्ठिव, इन्दौर (म.प्र.)
फोन : 0731-4977076, 97130-92737, 97130-37737, 79999-78894, 99075-27914

www.homoeopathyure.in, www.aarogyahomoeopathyindore.com Email: arpit Chopra23@



Prostate cancer suspected with High...

YouTube - Dr Arpit Chopra's Su...
9 Jan 2023

PROSTATE CANCER 95 GM PROSTATE RAISE...

YouTube - Dr Arpit Chopra's Su...
16 Aug 2021

VARICOCELE | Urological Disease...

YouTube - Dr Arpit Chopra's Su...
10 Nov 2022

BPH PROSTATOMEGALY &...

YouTube - Dr Arpit Chopra's Su...
26 May 2021

Prostatomegaly Patient Treatment at Aarogya...

YouTube - Dr Arpit Chopra's Su...
1 month ago

Prostate Carcinoma responded by Dr Arni

Prostate Enlargement Treatment Without...

YouTube - Dr Arpit Chopra's Su...
15 Mar 2021

Prostate Carcinoma Patient From Multai M...

YouTube - Dr Arpit Chopra's Su...
26 Aug 2023

Prostate Enlargement | BPH | Prostate cancer...

YouTube - Dr Arpit Chopra's Su...
9 Dec 2021

Prostate enlargement Prostatomegaly Benig...

YouTube - Dr Arpit Chopra's Su...
28 May 2023

Prostate cancer suspected with High...

YouTube - Dr Arpit Chopra's Su...
9 Jan 2023

PROSTATE CANCER 95 GM PROSTATE RAISE...

bodyScans

DEPARTMENT OF RADIOLOGY & IMAGING

NAME OF Patient: MR. GYANENDRA SINGH GOUD
Date: 15/01/2024
Ref By: DR. ARPIT CHOPRA JAIN

USG FINDINGS: USG ABDOMEN

LIVER: Measures 15.4cm, normal in size. Parenchyma echo-intensity is homogeneous. Intrahepatic biliary radicles are unobstructed.

GALL BLADDER: Normal distension, thin walled no calculi seen. CBD and Portal vein is normal in caliber.

SPLEEN: Measures 8.4cm in size. Parenchyma is normal. Spleen flexa vessels are unobstructed.

PANCREAS: Normal in size, all segments show normal parenchyma sub-structure. Tercerata duct is unobstructed.

RIGHT KIDNEY: Reveals normal size (10.4cm), shape and position. Cortical thickness and calyculations are normal. C/M dilatation is fair. Pelvicalyceal systems are unobstructed. Right ureter is unobstructed.

LEFT KIDNEY: Reveals normal size (11.3cm), shape and position. Cortical thickness and calyculations are normal. C/M dilatation is fair. Concretion of 3.0mm seen. Pelvicalyceal systems are unobstructed. Left ureter is unobstructed.

URINARY BLADDER: This walled, normal distension and no calculus is visualized. Pre void - 500cc, POST - 20cc.

PROSTATE: Normal in size and normal parenchyma echo intensity. No free fluid seen.

USG INTERPRETATION: LEFT RENAL CONCRETION.

After Dr Arpit Chopra Jain Modern Homoeopathy

RADIOLOGIST: DR. JAGDISH KUMAR GUPTA (M.D.)
Reg. No. 5254

DRN | Prostate Cancer...

YouTube - Dr Arpit Chopra's Su...
22 Jun 2023

Prostatomegaly 50 gm with 114 ml PVR cured...

YouTube - Dr Arpit Chopra's Su...
3 Sept 2021

BPH PROSTATOMEGALY &...

YouTube - Dr Arpit Chopra's Su...
13 Jan 2022

Prostate Enlargement | BPH | Prostate cancer...

YouTube - Dr Arpit Chopra's Su...
8 Jun 2023

Cancer Patient From Bihar Treatment at Dr...

YouTube - Dr Arpit Chopra's Su...
8 Sept 2023

Prostate & Renal stone Patient From Ajmer...

Prostate Enlargement

प्रोस्टेट का सफल इलाज बिना ऑपरेशन 2 साल परमा

18:40

सर्वोत्तम स्टोरी

YouTube Prostatomegaly 50 g

4:59

Aarogya Super Speciality...
Fatty liver grade 2 & BPH Pro...

Dr. M. S. Gill
MBBS, DMRP
Reg. No. 7038

GILL SONO CENTRE
304, Jankar Marg, INDORE-472 011
No. : 075413307, 9752094903
PLOT No. 214

29th JANUARY 2024

Mr. Gyanendra Gour

Dr. Arpit Chopra (Jain) MD

SONOGRAPHY OF THE WHOLE ABDOMEN:

Liver - Enlarged, Hepatic span - 18.5 cm. Increase in echogenicity of the hepatic Parenchyma with poor visualization of intrahepatic vessel ladders. Grade - II Normal portal vein caliber. No evidence of cyst or abscess.

Gall bladder - in this wall its contents are clear. No biliary strictures. CBD - Normal.

Pancreas & spleen etc of normal size revealing their usual architecture.

Both kidneys are normal in size shape & position. Their parenchymal echotexture are normal. Azygos renal vessels dilatation. No evidence of renal calculi. Ureteral peristaltic system. Both ureters are unobstructed.

IVC & abdominal aorta are normal. No lymphadenopathy.

Urinary bladder - Normal size & shape. Walls are thin. No intraluminal. No residual volume.

Prostate - Enlarged - 62x4x35mm (C=40x30x20mm). Spherical in shape. No free fluid enlargement. Heterogeneous echos. No focal lesion. App. vs. 40 gms.

No ascites. No pleural effusion.

IMPRESSION: Liver - Fatty infiltration, Grade - II. Slight enlargement of prostate.

There is dilatation of the lower legs through azygos. Normal Peristaltic Movements seen. No evidence of obstruction. / congestion. Hemodial gap - 10mm

Before Treatment

Prostate Enlargement Treatment Without...

YouTube - Dr Arpit Chopra's Su...
15 Mar 2021

Prostate Carcinoma Patient From Multai M...

YouTube - Dr Arpit Chopra's Su...
26 Aug 2023

Prostate Enlargement | BPH | Prostate cancer...

YouTube - Dr Arpit Chopra's Su...
9 Dec 2021

Prostate enlargement Prostatomegaly Benig...

YouTube - Dr Arpit Chopra's Su...
28 May 2023

Prostate cancer suspected with High...

YouTube - Dr Arpit Chopra's Su...
9 Jan 2023

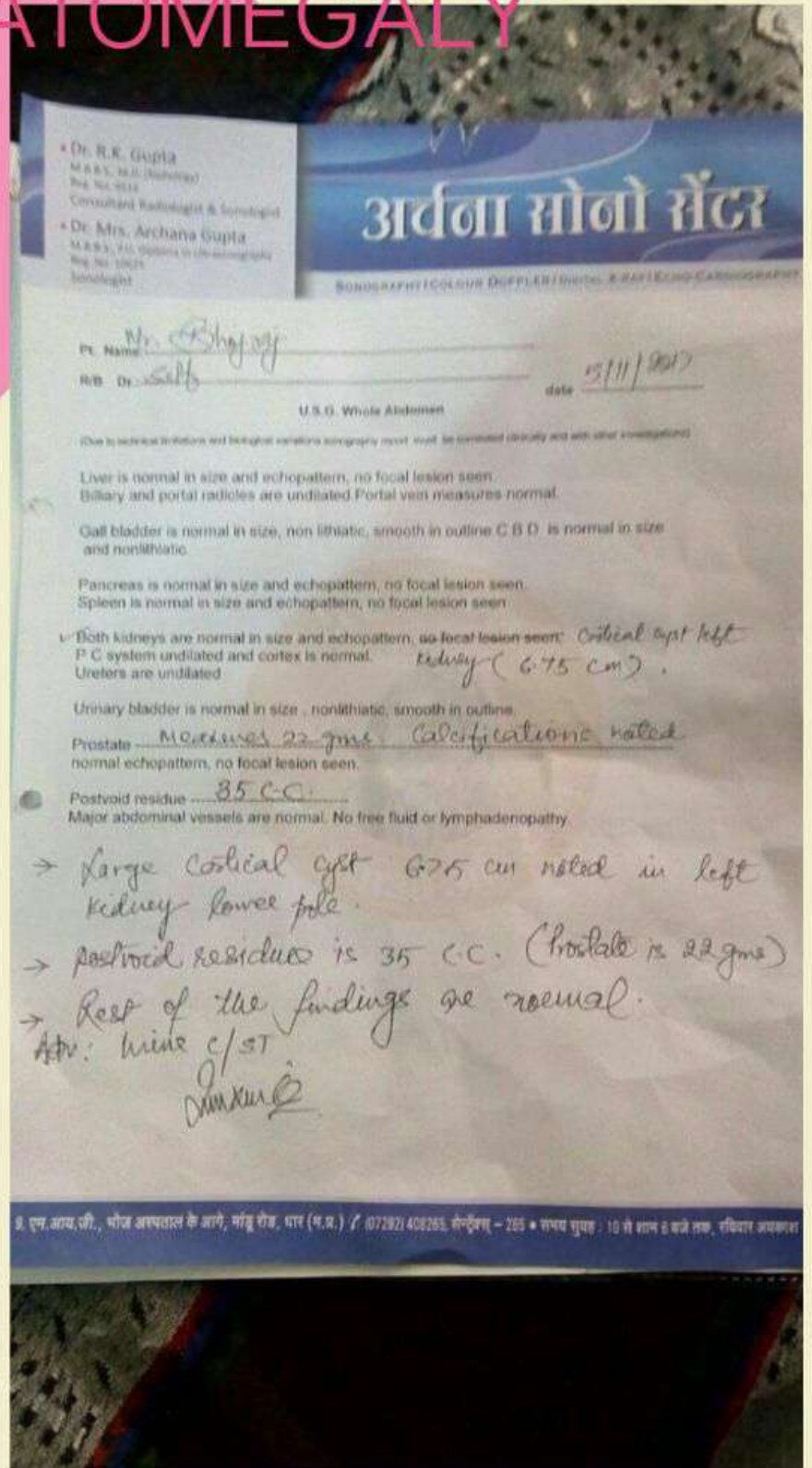
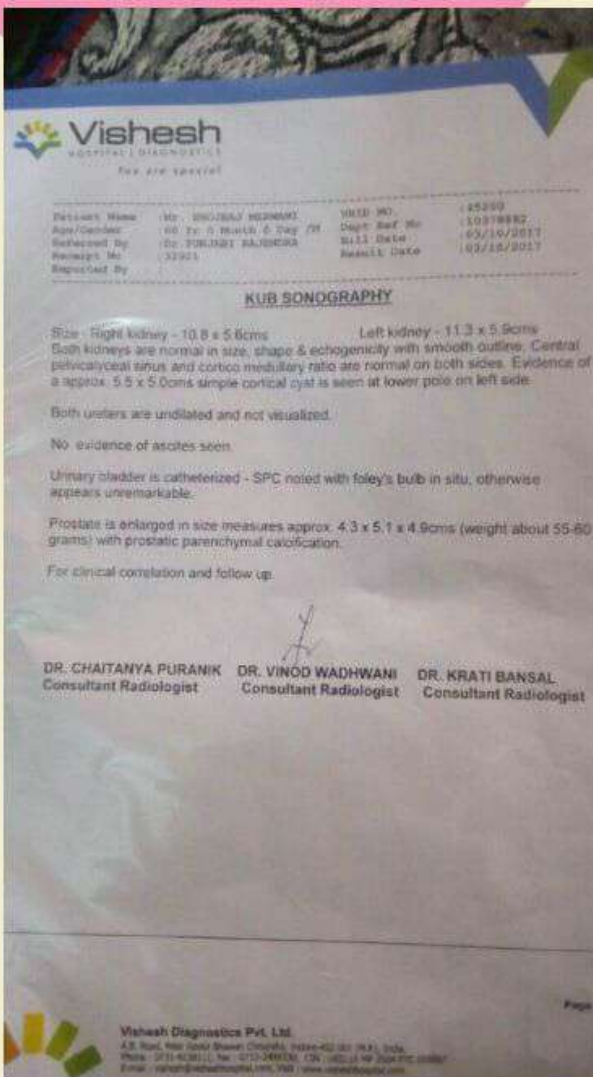
PROSTATE CANCER 95 GM PROSTATE RAISE...

Never lose hope

To see a world in a grain of sand
And a heaven in a wild flower
Hold infinity in the palm of your hand
And eternity in an hour

CURED PROSTATOMEGALY

Pre & Post Treatment Report



TEST REPORT

Mr. LAKHAN SINGH

PID NO: P31170065158

Age: 36 Year(s) Sex: Male

Reference: Dr.ARPIT CHOPRA

Sample Collected At:
ROYAL DIAGNOSTICS SOLUTIONS
GH41 SCHEME NO 54,VIJAY NAGAR
INDORE.

VID: 31170165737

Registered On:
09/02/2018 06:10 PM

Collected On:
09/02/2018

Reported On:
09/02/2018 07:41 PM

Investigation

Testosterone (Total)
(Serum,ECLIA)

Observed Value

203.5

Unit

ng/dL

Biological Reference Interval

260-1000

-- End of Report --

TEST REPORT

Mr. LAKHAN SINGH

PID NO: P31170072953

Age: 36 Year(s) Sex: Male

Reference: Dr.ARPIT CHOPRA

Sample Collected At:
ROYAL DIAGNOSTICS SOLUTIONS
GH41 SCHEME NO 54,VIJAY NAGAR
INDORE.

VID: 31170173704

Registered On:
15/03/2018 03:56 PM

Collected On:
15/03/2018

Reported On:
15/03/2018 05:42 PM

Investigation

Testosterone (Total)
(Serum,ECLIA)

Observed Value

378.0

Unit

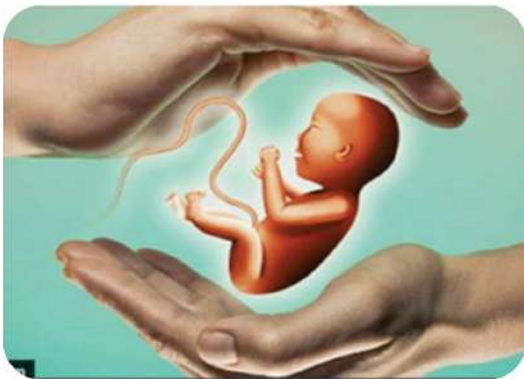ng/dL

Biological Reference Interval

260-1000

-- End of Report --

Infertility





Pramod Sahu





MALE INFERTILITY



Anshu Sharma
Indore



Common Causes is Male Infertility





Khilashwari Sahu
Razim Garibnagar, C.G.




FALLOPIAN TUBE BLOCKAGE




before treatment




MANISHI MASATKAR



Infertility



Before Treatment



KRITIKA SHRIVASTAV



Service Project Infrastructure: Making Medical Care Accessible to All

"Medical facilities should be accessible to the common man in every way." Dr. Arpit Chopra Jain

To make his groundbreaking medical invention available to the general public, Professor Dr. Arpit Chopra Jain has established the Aarogya Super Speciality - Modern Homoeopathy Clinic, equipped with state-of-the-art facilities, at Janjirwala intersection in the heart of Indore city. At this clinic, patients have access to comprehensive consultation, diagnosis, and treatment for various diseases, all under one roof.

In addition, a dedicated consultation room for online patients has been set up to offer virtual consultations. Medicines are delivered through courier services, ensuring that even the most serious conditions can be treated from the comfort of one's home. Dr. Arpit Chopra Jain's initiative ensures that high-quality healthcare is not just limited to in-person visits but is also accessible to those in distant locations.





Dr. Arpit Chopra Jain: A Commitment to Service and Responsibility

Dr. Arpit Chopra Jain, raised in a family of doctors, embodies the true essence of a dedicated medical professional. With a deep sense of responsibility toward human welfare, he has revolutionized healthcare through his groundbreaking invention of Super Speciality Modern Homoeopathy treatment. His work has provided a new direction in treating complex diseases, ensuring that even those who once felt hopeless have found relief.

campaign to combat sickle cell anemia, Dr. Arpit Chopra Jain is also working tirelessly in tribal areas. His efforts contribute significantly to the permanent and successful treatment of this genetic disorder, further reflecting his unwavering commitment to the welfare of humanity.



Dr. Arpit Chopra Jain also organizes medical camps aimed at diagnosing complex diseases, providing free consultations to those in need. His sense of duty was especially evident during the devastating COVID-19 pandemic, where he took extraordinary measures to help his community. Understanding the gravity of the situation, he distributed free Corona prevention medicines to approximately 2,25,000 people, including Corona Warriors, potentially saving many lives.





Dr. Arpit Chopra Jain exemplifies what it means to be a physician who balances medical practice with social responsibility, continuing to make a profound impact on both individual lives and society as a whole.



Recognizing the significance of his role, Dr. Arpit Chopra Jain extends his responsibilities beyond medical practice. He considers it his moral and national duty to contribute to various social service activities. Along with treating complicated medical conditions, Dr. Arpit Chopra Jain is committed to shaping the future of homoeopathy. He actively mentors and educates new students entering the field, helping them gain the knowledge necessary to advance in medical science.





Samman Awards: A Tribute to Responsibility and Service

"Respect received from society increases responsibility." Dr. Arpit Chopra Jain

Dr. Arpit Chopra Jain believes that when one contributes responsibly and at the right time, society offers its respect. However, with that respect comes an even greater sense of responsibility.

Dr. Arpit Chopra Jain, through his groundbreaking invention of the Arogya Super Speciality Modern Homoeopathy medical system and his numerous social contributions, has garnered widespread recognition. His dedication to improving the health and well-being of others has not gone unnoticed. He has been honored by many prominent ministers, intellectuals, and senior artists across various dignified platforms. These awards have been bestowed upon him by social, national, and international institutions, further acknowledging his remarkable contributions to the field of medicine and humanity.

This recognition only fuels Dr. Arpit Chopra Jain's determination to continue serving society with even greater dedication and responsibility.

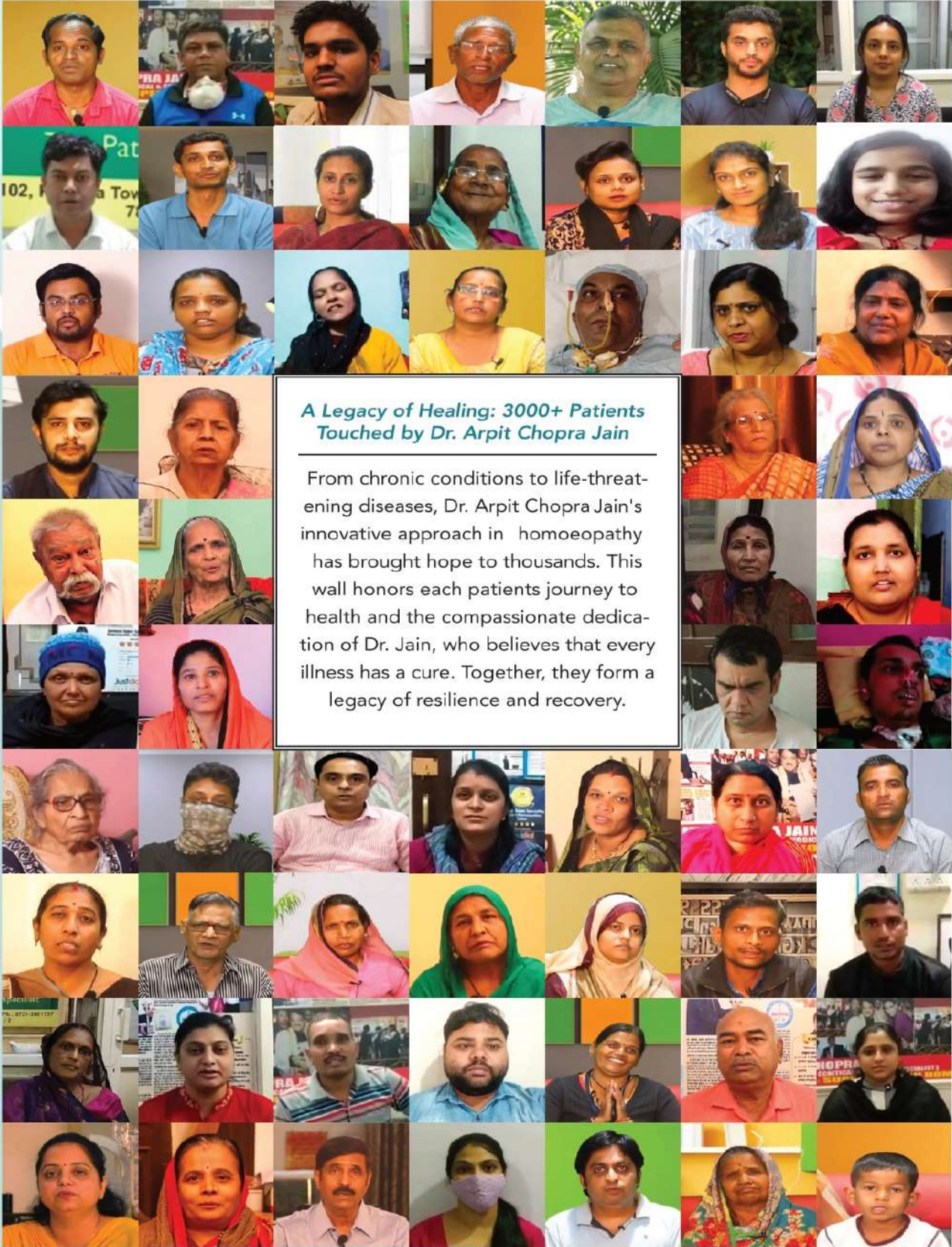






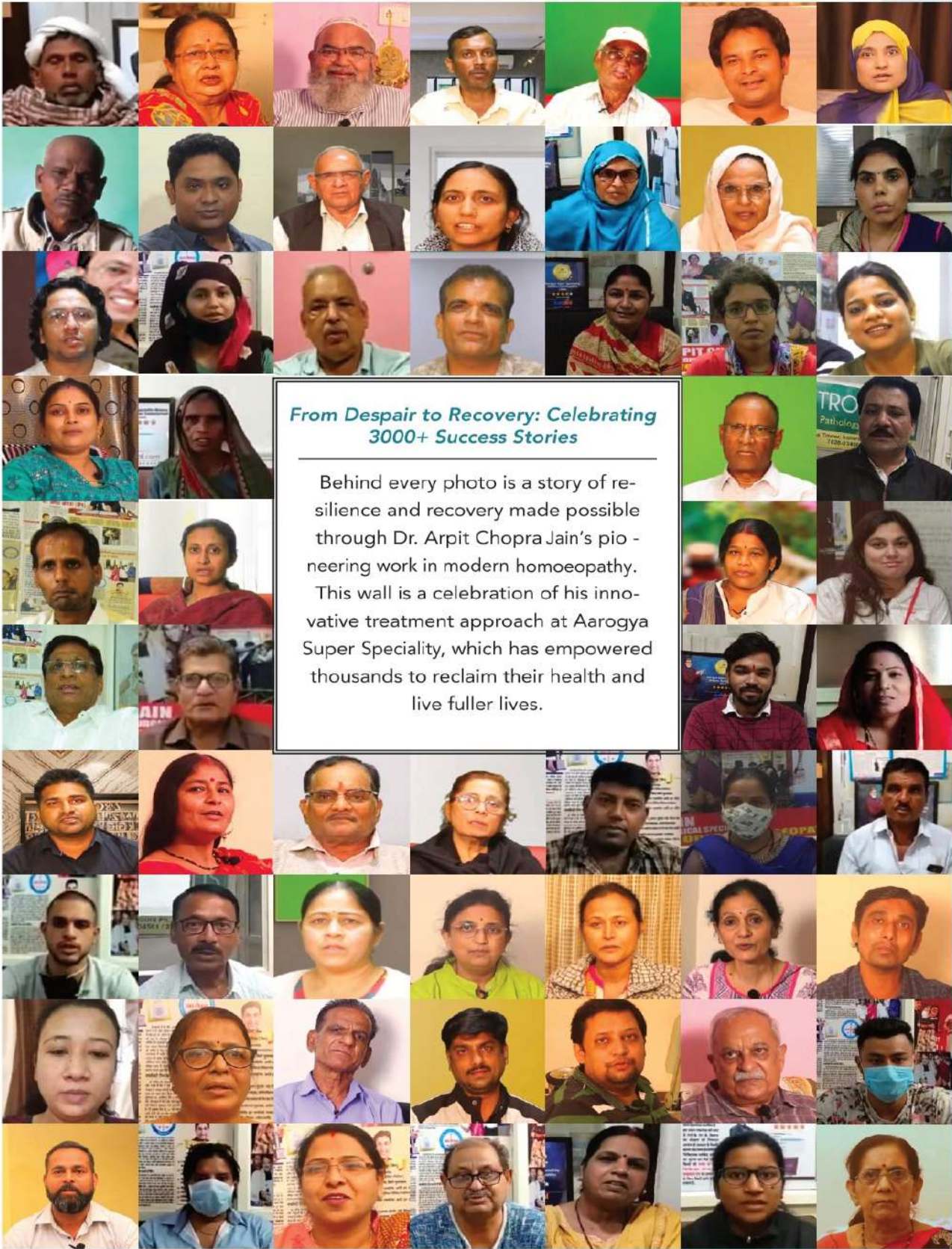




A Legacy of Healing: 3000+ Patients Touched by Dr. Arpit Chopra Jain

From chronic conditions to life-threatening diseases, Dr. Arpit Chopra Jain's innovative approach in homoeopathy has brought hope to thousands. This wall honors each patients journey to health and the compassionate dedication of Dr. Jain, who believes that every illness has a cure. Together, they form a legacy of resilience and recovery.



From Despair to Recovery: Celebrating 3000+ Success Stories

Behind every photo is a story of resilience and recovery made possible through Dr. Arpit Chopra Jain's pioneering work in modern homoeopathy. This wall is a celebration of his innovative treatment approach at Aarogya Super Speciality, which has empowered thousands to reclaim their health and live fuller lives.



Thank
You!



Possible solutions to complex, incurable and impossible diseases. Harmless, quick, economical and permanent treatment system, Homoeopathy of the future, Thank you for giving your valuable time to Super Speciality Modern Homoeopathy treatment system.


May you always live a happy life by staying physically,
mentally and socially healthy and fulfill the WHO standards


This is my wish, This is my effort...

Aarogya Super Speciality Modern Homoeopathy

101-104, First Floor, Krishna Tower, Opposite Curewell Hospital
New Palasia, INDORE (M.P.)

ONLINE CONSULTATION ALSO AVAILABLE

 @ 99075-27914, 79999-78894
@ 97130-92737, 97130-37737

 aarogya101

 [instagram.com/aarogyahomeopathy](https://www.instagram.com/aarogyahomeopathy)

 www.aarogyahomeopathyindore.com

www.aarogyahomeopathyindore.com
www.homoeopathycure.in
besthomoeopapathdoctorind.com

email : arpitchopra23@gmail.com, aarogyamodernhomeopathy@gmail.com

You Tube Link  - [drarpitchopramodernhomeopathic](https://www.youtube.com/channel/UCdrarpitchopramodernhomeopathic)